

ORIGINAL RESEARCH

Prevalence of the Mental Foramen Location in an Indian Subpopulation: A Retrospective Orthopantomogram Study

Jahnvi Bhagat¹, T Dhara Shah², Gabriela Fernandes³

ABSTRACT

Background: This study aimed at documenting information on the horizontal and vertical locations of mental foramen (MF) in a panoramic radiograph. We have also analyzed its presence and symmetry in the adult and pediatric population. Our research findings can be used as reference material by the dental practitioners of Western India while performing clinical procedures that involve MF.

Materials and Methods: A total of 104 panoramic radiographs were evaluated, of which 98 were adults and 6 were pediatric patients. Each radiograph was traced to record the horizontal locations as well as symmetry. *t*-test was employed for statistical analysis.

Results: The most common appearance of MF was below the apex of the second premolar in adults and at the apex of the first premolar as well as between the apices of the first and second premolar for the pediatric population. The number of MF present was significantly higher below the apex of the second premolar in adults ($P < 0.01$). There was no statistical significant difference between the symmetry of the MF, and the adults and pediatric population demonstrated symmetry with regard to the location of the foramen ($P > 0.01$).

Conclusions: Determining the positional variation and symmetry of MF is important for isolation of mental nerves and vessels when administering local anesthesia and performing surgeries. We, therefore, stress the importance of accurate radiographic identification of MF and interpretation.

Keywords: Orthopantomogram, Mental foramen, *t*-test.

How to cite this article: Bhagat J, Shah D, Fernandes G. Prevalence of the Mental Foramen Location in an Indian Subpopulation: A Retrospective Orthopantomogram Study. *Int J Oral Care Res* 2018;6(2):89-92.

Source of support: Nil

Conflicts of interest: None

INTRODUCTION

Mental foramen (MF) is one of the most important and studied foramina of the mandible.^[1,2] The mandibular foramen is an opening seen on the medial (internal) aspect of the mandible which leads into a funnel-like

mandibular canal that opens at the MF on the antero-lateral surface of the mandible.^[2] The mandibular nerve passes through this canal, travels obliquely forward, and takes a turn from the incisal region to reach the MF and exit as inferior alveolar nerve and vessels.^[2] It is this inferior alveolar nerve that branches into the mental nerve which would provide sensory innervation the skin of the chin, the gingiva, and mucosa in the region of anterior teeth and lower lip.^[2] It is of paramount importance that the surgeons know of the positioning of the MF, especially surgical procedures such as impacted tooth removal, apicoectomy, osteotomies, excision of tumors, or enucleation of cysts and for nerve blocks.^[1] Conducting these procedures without any knowledge about the positioning of the MF can injure the mental nerve or even compress it causing loss of sensory innervation. Even during implant placement, it is critical to know the presence of any anterior loop of the mental nerve mesial to its foramen, to prevent nerve injury or even paralysis.^[2] The best way to detect the location of MF in through panoramic radiographs over computed tomography scans as there is lesser exposure to the patients.^[1,3]

From the number of studies that have been conducted for the positioning of MF all round the world, it has been inferred that the location of the MF differs with different ethnic groups, with gender, and within the population of the same ethnic group.^[3-6] There are various positions under which the location of the MF can be classified such as at the apex of the first premolar, between the apices of the first and the second premolar, at the apex of the second premolar, between the apices of the second premolar and first molar, and on the mesial aspect of the first molar. A study was conducted among Turkish population by Gungor *et al.*^[7,8] to investigate the most common position of the MF, in which they reported that the most common position of the MF was between the first and the second premolar (71.5%). In addition, 90.4% of patients showed a symmetry with respect to the position on the left and right side of the mandible. A similar study was conducted among the Saudi population by Kamran Bokhari *et al.*^[9] with a sample size of 900 OPGs, whereby the most common MF position concluded was between the two premolars on both the sides of the mandible (72%).

^{1,2,3}Private Practitioner

^{1,2,3}Private Practitioner, Mumbai, Maharashtra, India

Corresponding Author: Dr. Jahnvi Bhagat, Private Practitioner, Mumbai, Maharashtra, India. e-mail: Jcbhagat26@gmail.com

Aims and Objectives

The aim and objectives of this study are as follows:

- i. To assess the positioning of the MF most frequently seen within Indian population along the horizontal axis through panoramic radiographs.
- ii. To analogize the positioning of the MF on both the sides of the mandible.
- iii. To place the emphasis on the difference in the position of the MF between adult and pediatric patients.

MATERIALS AND METHODS

This study was conducted at a private dental clinic in the metropolitan city of Mumbai which has a uniform mix of the Indian population. This was a retrospective study that was carried out to analyze the most common position of the MF among Indians. Our sample size consists of a 104 orthopantomographs, of which 98 were adult patients and 6 were pediatric patients. Not only was the position of the MF recorded but also its symmetry on both sides. After the evaluation of 104 OPGs, *t*-test was employed to decode the data which were then inserted into an Excel sheet and analyzed with SPSS. These samples were taken ethically and with the full consent of the private practitioner for this study.

The position of the MF is classified under two categories:

- A. Along the horizontal axis:
 - Below the apex of the first premolar
 - Between the apices of the first and second premolar
 - Below the apex of the second premolar
 - Between the apices of the second premolar and first molar
 - On the mesial aspect of the first molar.

The result retrieved after having studied the 104 panoramic radiographs was inserted into diagrammatic graphs for easy visualization and understanding. The results of this study were reviewed and assessed by two other investigators.

Inclusion Criteria

The following criteria were included in the study:

- 98 adult patients and 6 pediatric patients
- None of the patients had any significant deformity or pathology
- Patient with a full set of teeth was chosen that had not gone under orthodontic treatment
- New OPGs of the patients were chosen and not their old OPGs.

Exclusion Criteria

The following criteria were excluded from the study:

- Complete clarity orthopantomograms were studied and not the ones with defects
- Patients who have undergone any osteotomy or other surgical procedures
- Patients having pathologies in the remolar region (may be benign or malignant) such as granuloma's, cysts, and tumors
- Orthodontic patients
- Patients showing crowding of teeth in the premolar region.

Statistical analysis: The data was coded and entered into Microsoft Excel spreadsheet. Analysis was done using SPSS version 15 (SPSS Inc. Chicago, IL, USA) Windows software program. Descriptive statistics were calculated. Statistical tests applied were Independent *t*-test, paired *t*-test and McNemar test. Level of significance and confidence level were set at 5% and 95%, respectively.

RESULTS

This study was conducted to study 104 orthopantomograms to find the most frequent position of the MF among Indian population. Of these 104 OPGs, 6 were pediatric patients and the rest were adult patients. These OPGs were studied even to find the symmetry of the foramens on both the lateral sides of the mandible.

On assessing all the 104 OPGs for the location of the MF on both the sides, it was inferred that the most common location of the MF was below the apex of the second premolar [Figures 1 and 2]. The rest of the findings are as follows:

- 36.5% - below the apex of the second premolar
- 30.8% - between the apices of the first and second premolar
- 17.3% - below the apex of the first premolar
- 12.5% - between the apices of the second premolar and the first molar
- 2.9% - on the mesial aspect of the first molar.

Based on the symmetry:

- 56.7% - symmetrical on the left and right side
- 43.3 - no symmetry seen on the left and right side of the mandible.

DISCUSSION

MF is one of the important foramens of the mandible primarily because the inferior alveolar nerve and vessels exit it on the lateral aspect of the mandible and give rise to the mental nerve which provides sensory innervation

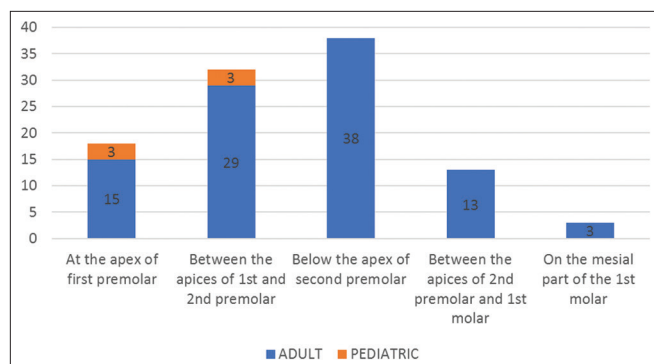


Figure 1: Location of the position of the mental foramen

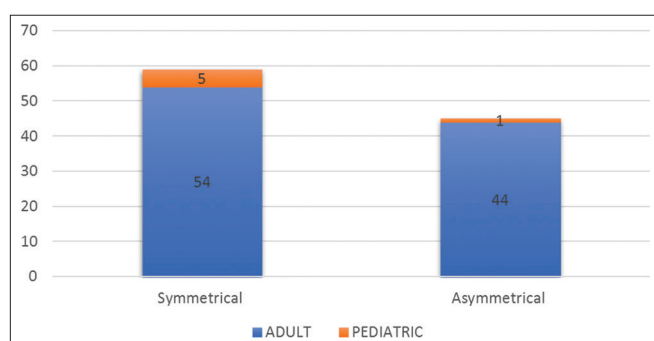


Figure 2: Assessment of the symmetry of the mandibular foramen in adult and paediatric patients

to the skin of the chin, gingiva over the mandibular, anteriors, and the lower lip.^[10-13] Hence, it is of prime importance for the surgeons to be aware of where the MF is located in a given patient, especially during nerve blocks and mainly during osteotomy, and other surgeries to prevent injuring of the mental nerve and prevent it from compressing during implant procedures.^[2,4,14] Even periodontal surgeries such as flap surgeries in that region have to be done with exacting precision so as to prevent damaging the nerve.

Damage to the neurovascular bundle exiting from the MF (mental neuropathy) can lead to a number of neurological problems such as neurotmesis or neuropraxia and even the "numb chin sign."^[15] Usually, the location of the MF is toward the lower border of the mandible in childhood and rises up halfway through the mandible as the age increases. It is important to know the anatomy of the foramen because it appears as a round radiolucency near the apical region of the mandibular premolars, which could be mistaken for a periapical lesion. However, it has been concluded that the most common position of the MF is between the two premolars, in accordance to the majority of the studies that have been published.^[16-20]

During the evaluation of the orthopantomograms, the MF did not appear identical in all the patients. We came across certain OPGs where the foramen appeared distinct and in continuation with the mandibular canal,

where the inferior alveolar canal could be easily traced. Few OPGs showed distinct foramen; however, they were a little away from the mandibular canal. Certain OPGs did not have a clear border, making it difficult to mark the foramen and identify its shape and size. There were certain OPGs in which the MF was not distinguishable at all; however, we refrained from including those OPGs into the sample, whereas in contrast, certain OPGs showed multiple radiolucencies in which case the radiolucency closest to the mandibular canal was taken into consideration.

Sometimes, even a minor mistake in the endodontic treatment in the premolar region can cause untoward inflammatory, physical, and chemical injury to the nerve bundle, without the knowledge of its exact position. Hence, to prevent further complications, it is important for dentists to know the location of the MF. In case the exact location of the person cannot be determined due to certain reasons, such studies help them to know the most common position in their particular population.

A study carried out in Saudi population reported that the most common position of the MF is near the apex of the second premolar, even studies conducted by Igbigbi and Lebona^[21] in Malawians and Mbajiorgu *et al.*^[22] among Zimbabweans mandibles reported that the most common position of the MF is near the apex of the second premolar followed by second most common position being between the second premolar and first molar. Santini and Land^[23] studied the British population, whereas Green *et al.*^[24] studied Chinese mandibles and they reported the most common position for the MF to be between the first and second premolars.

We, thus, infer from the above results from various ethnicities and populations that the most common position of the MF among the population of metropolitan Mumbai is similar to the Malawian and Zimbabwean population (i.e., below the apex of the second premolar), followed by the second most common position being between the first and the second premolars.

CONCLUSIONS

Hence, after assessing these panoramic radiographs, we conclude that the MF is most frequently located below the apex of the second premolar and must hence be taken into consideration during implant placement procedures.

REFERENCES

1. Direk F, Uysal II, Kivrak AS, Fazliogullari Z, Unver Dogan N, Karabulut AK, *et al.* Mental foramen and lingual vascular canals of mandible on MDCT images: Anatomical study and review of the literature. *Anat Sci Int* 2018;93:244-53.
2. Greenstein G, Tarnow D. The mental foramen and nerve:

- Clinical and anatomical factors related to dental implant placement: A literature review. *J Periodontol* 2006;77:1933-43.
3. Aminoshariae A, Su A, Kulild JC. Determination of the location of the mental foramen: A critical review. *J Endod* 2014;40:471-5.
 4. Parnami P, Gupta D, Arora V, Bhalla S, Kumar A, Malik R, et al. Assessment of the horizontal and vertical position of mental foramen in indian population in terms of age and sex in dentate subjects by pano-ramic radiographs: A Retrospective study with review of literature. *Open Dent J* 2015;9:297-302.
 5. Laher AE, Wells M, Motara F, Kramer E, Moolla M, Mahomed Z, et al. Finding the mental foramen. *Surg Radiol Anat* 2016;38:469-76.
 6. Paraskevas G, Mavrodi A, Natsis K. Accessory mental foramen: An anatomical study on dry mandibles and review of the literature. *Oral Maxillofac Surg* 2015;19:177-81.
 7. Gungor E, Aglarci OS, Unal M, Dogan MS, Guven S. Evaluation of mental foramen location in the 10-70 years age range using cone-beam computed tomography. *Niger J Clin Pract* 2017;20:88-92.
 8. Gungor K, Ozturk M, Semiz M, Brooks SL. A radiographic study of location of mental foramen in a selected turkish population on panoramic radiograph. *Coll Antropol* 2006;30:801-5.
 9. Bokhari AA, Mustafa AB, Hdban Y, Saleh M, Mofareh A. Position of mental foramen among Saudi population: A radiographic study. *Int J Exp Dent Sci* 2016;5:109-12.
 10. Alam MK, Alhabib S, Alzarea BK, Irshad M, Faruqi S, Sghaireen MG, et al 3D CBCT morphometric assessment of mental foramen in arabic population and global comparison: Imperative for invasive and non-invasive procedures in mandible. *Acta Odontol Scand* 2018;76:98-104.
 11. Li Y, Yang X, Zhang B, Wei B, Gong Y. Detection and characterization of the accessory mental foramen using cone-beam computed tomography. *Acta Odontol Scand* 2018;76:77-85.
 12. Stoneman DW. The mental foramen. *Oral Health* 1965;55:659 passim.
 13. TEBO HG. Variations in position of the mental foramen. *Dent Items Interest* 1951;73:52-3.
 14. Ritter L, Neugebauer J, Mischkowski RA, Dreiseidler T, Rothamel D, Richter U, et al. Evaluation of the course of the inferior alveolar nerve in the mental foramen by cone beam computed tomography. *Int J Oral Maxillofac Implants* 2012;27:1014-21.
 15. Juodzbalys G, Wang HL, Sabalys G. Anatomy of mandibular vital structures. Part II: Mandibular incisive canal, mental foramen and associated neurovascular bundles in relation with dental implantology. *J Oral Maxillofac Res* 2010;1:e3.
 16. Srinivas N, Ramdurg P, Puranik SR, Sali K, Ingaleshwar P. The position of the mental foramen in the north and south indian populations. *Acta Med Acad* 2017;46:44-9.
 17. Charalampakis A, Kourkoumelis G, Psari C, Antoniou V, Piagkou M, Demesticha T, et al. The position of the mental foramen in dentate and edentulous mandibles: Clinical and surgical relevance. *Folia Morphol (Warsz)* 2017; doi: 10.5603/FM.a2017.0042.
 18. Sheikhi M, Kheir MK. CBCT assessment of mental foramen position relative to anatomical landmarks. *Int J Dent* 2016;2016:5821048.
 19. Ajmal M. Evaluation of mental foramen position from panoramic dental radiographs. *J Contemp Dent Pract* 2014;15:399-402.
 20. Gada SK, Nagda SJ. Assessment of position and bilateral symmetry of occurrence of mental foramen in dentate asian population. *J Clin Diagn Res* 2014;8:203-5.
 21. Igbigbi PS, Lebona S. The position and dimensions of the mental foramen in adult malawian mandibles. *West Afr J Med* 2005;24:184-9.
 22. Mbajjorgu EF, Mawera G, Asala SA, Zivanovic S. Position of the mental foramen in adult black zimbabwean mandibles: A clinical anatomical study. *Cent Afr J Med* 1998;44:24-30.
 23. Santini A, Land M. A comparison of the position of the mental foramen in chinese and british mandibles. *Acta Anat (Basel)* 1990;137:208-12.
 24. Green RM. The position of the mental foramen: A comparison between the southern (Hong kong) chinese and other ethnic and racial groups. *Oral Surg Oral Med Oral Pathol* 1987;63:287-90.