

## CASE REPORT

# Enhancement of Pink Esthetics by Surgical Removal of Molar-to-molar Gingival Hyperpigmentation

<sup>1</sup>Nawab Aftab, <sup>2</sup>Shivamurthy Ravindra, <sup>3</sup>Marenahalli Rangaraju Vivekananda, <sup>4</sup>Dasappa Shivaprasad  
<sup>5</sup>KN Madhushree, <sup>6</sup>CP Ranjini, <sup>7</sup>Surendran Atheena, <sup>8</sup>BK Tejaswi

## ABSTRACT

Pigmentation of gingiva is caused by deposition of melanin pigment. It occurs in all races of mankind. Gingival pigmentation is not a disease entity and it does not present itself as a medical problem. However, many people complain of dark gums, which is a major esthetic concern. In such patients, esthetic gingival depigmentation procedures can be performed and excellent results can be achieved. A case is reported here in which depigmentation was performed by a simple and effective surgical procedure using scalpel technique, which still serves as a gold standard for gingival depigmentation procedures.

**Keywords:** Gingiva, Gingival depigmentation, Melanin, Physiological pigmentation, Scalpel technique.

**How to cite this article:** Aftab N, Ravindra S, Vivekananda MR, Shivaprasad D, Madhushree KN, Ranjini CP, Atheena S, Tejaswi BK. Enhancement of Pink Esthetics by Surgical Removal of Molar-to-molar Gingival Hyperpigmentation. *Int J Oral Care Res* 2017;5(3):257-259.

**Source of support:** Nil

**Conflict of interest:** None

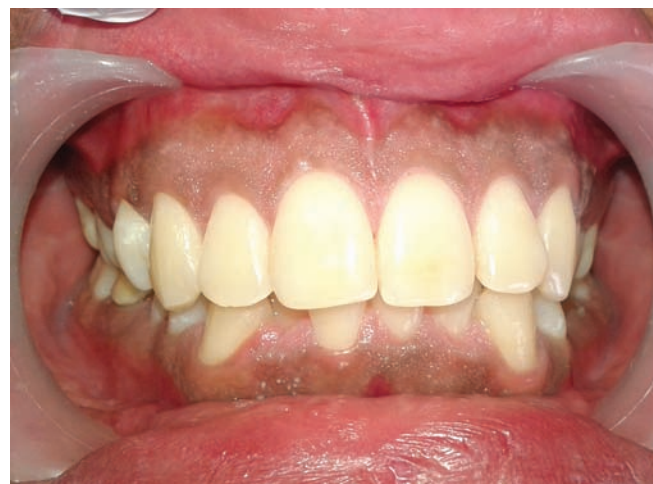## INTRODUCTION

Gingival color is determined by various factors like number and size of the blood vessels, epithelial thickness, quantity of keratinization, and pigments within the gingival epithelium. Melanin, carotene, reduced hemoglobin, and oxyhemoglobin are the main pigments contributing to the normal color of the oral mucosa.<sup>1</sup> The most common natural pigment contributing to endogenous pigmentation of the gingiva is melanin, which is a brown pigment. Melanin pigmentation is known to be caused by melanin granules within the gingival epithelium.<sup>2</sup> Melanin is deposited by melanocytes, mainly located intertwined between the basal and the suprabasal cell

layers of epithelium.<sup>3,4</sup> Clinically, melanin pigmentation is completely benign and does not present a medical problem; dark gums may pose a major esthetic concern for many people, when it is visible during speech and smile.<sup>5</sup> Hence, it demands for cosmetic therapy in people having fair complexion with moderate or severe gingival pigmentation,<sup>6</sup> especially with a high smile line or excessive gingival display while smiling. Gingival depigmentation is a periodontal plastic surgical procedure where gingival hyperpigmentation is removed or reduced using various techniques to achieve better esthetic outcomes.

## CASE REPORT

A 23-year-old male patient visited the Department of Periodontics and Oral Implantology, Sri Hasanamba Dental College & Hospital, Hassan, Karnataka, India, with the chief complaint of blackish gums (Fig. 1). Oral examination revealed pronounced bilateral melanin-pigmented gingiva in maxillary and mandibular regions. The patient requested for esthetically better gums; hence, considering the patient's concern, a surgical gingival deepithelialization procedure using the gold standard scalpel deepithelialization technique was planned. The entire procedure was explained to the patient and written consent was obtained. To rule out any contraindication for surgery, a complete medical examination, family history, and blood investigations were done. Oral prophylaxis was done before the surgery.



**Fig. 1:** Gingival melanin pigmentation (preoperative)

<sup>1,5-8</sup>Surgeon, <sup>2</sup>Principal, Professor, and Head, <sup>3</sup>Reader, <sup>4</sup>Senior Lecturer

<sup>1-8</sup>Department of Periodontics and Oral Implantology, Sri Hasanamba Dental College & Hospital, Hassan, Karnataka India

**Corresponding Author:** Nawab Aftab, Surgeon, Department of Periodontics and Oral Implantology, Sri Hasanamba Dental College & Hospital, Hassan, Karnataka, India, Phone: +919743186962, e-mail: nawab.aftu@rediffmail.com

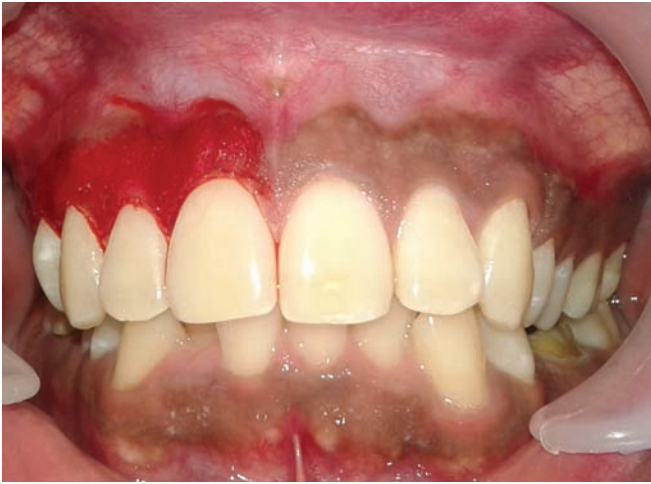

Fig. 2: Removal of pigment layer

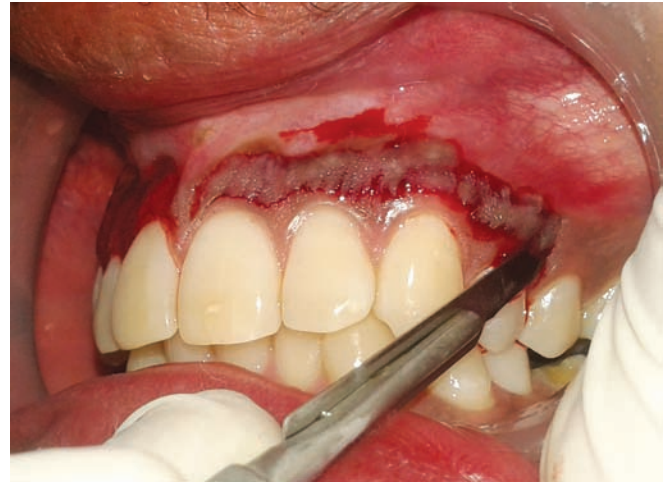

Fig. 3: Split thickness flap using scalpel

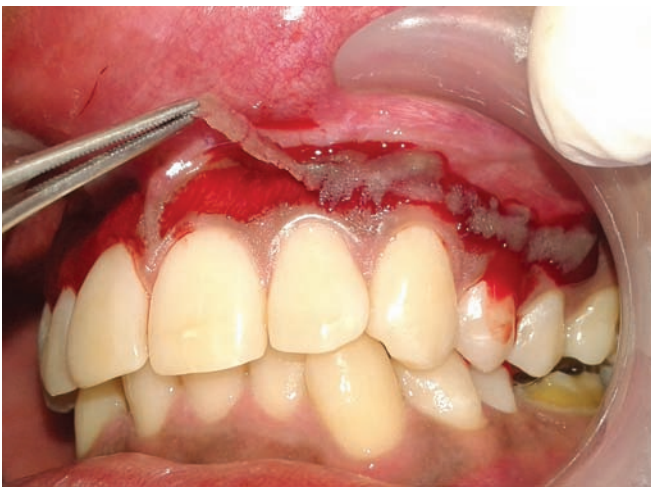

Fig. 4: Continuous band of split thickness flap

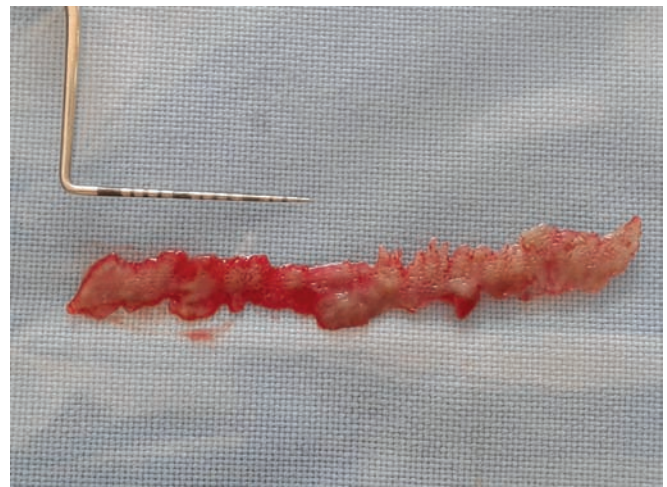


Fig. 5: Excised pigmented epithelium

## SURGICAL PROCEDURE

Lignocaine with adrenaline (1:2,00,000) local anesthesia was administered as nerve block and infiltration. Using a #15 scalpel blade, the pigmented layer was removed by split thickness flap design from maxillary molar-to-molar region, maintaining the normal architecture of the gingiva (Figs 2 to 6). Intraoperative bleeding was controlled using sterile gauze pressure pack. The exposed depigmented surgical site was covered using periodontal dressing Coe-pack for 1 week (Fig. 7). The patient was prescribed amoxicillin and clavulanic acid 625 mg twice daily for 5 days and aceclofenac–paracetamol combination twice daily for 3 days; postoperative instructions were advised. A 0.2% chlorhexidine mouthwash was advised 3 to 4 times a day for 2 weeks.

## RESULTS

Patient's acceptance of the procedure was good. Healing process was uneventful with no postoperative pain, hemorrhage, and infection. No scarring was observed,

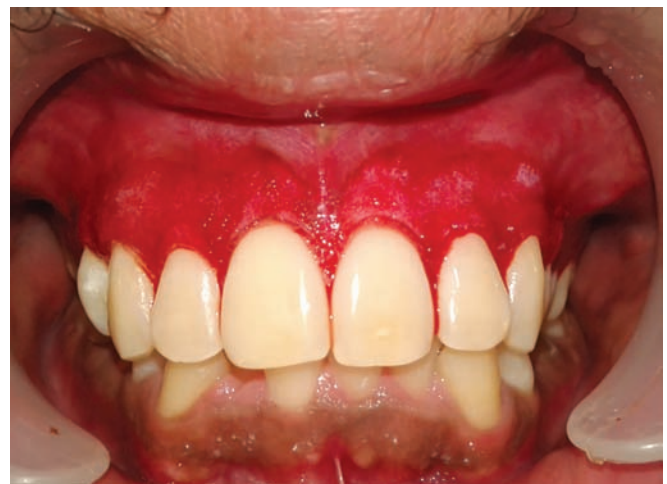

Fig. 6: Removal of pigment layer—deepithelialization

and results were excellent as perceived by the patient (Fig. 8). No repigmentation occurred for the initial 4 months (Fig. 9) follow-up. Patient has been put under long-term follow-up to monitor occurrence of any repigmentation.

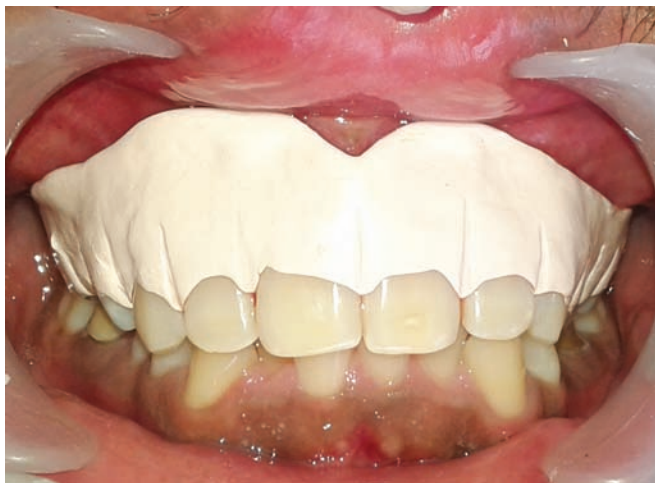

Fig. 7: Periodontal dressing

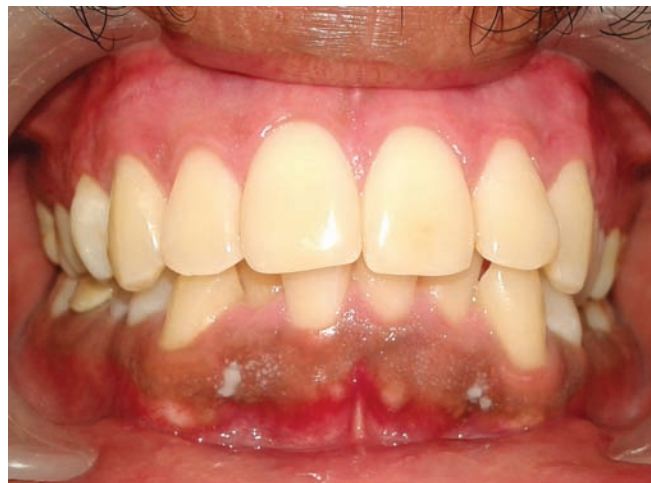

Fig. 8: One week postoperative healing

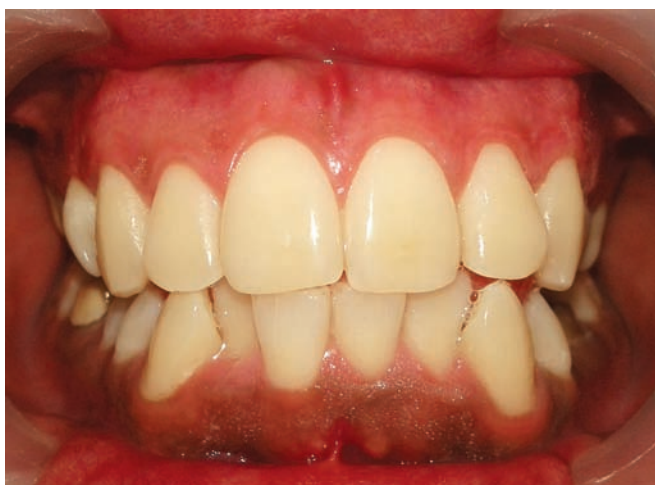

Fig. 9: Four months postoperative follow-up

## DISCUSSION

The surgical removal of undesirable pigmentation using scalpel is one of the first and still popular techniques to be employed. This particular procedure typically involves surgical removal of gingival epithelium along with a layer of the underlying connective tissue and allowing the denuded connective tissue to heal by secondary intention. The new epithelium that forms is devoid of melanin pigmentation.<sup>7</sup> Care must be taken to avoid exposing the underlying bone; hence, it should be removed in thin sections. All remnants of the pigment layer have to be removed to avoid chances of recurrences. In this particular case, the scalpel method of depigmentation showed better results from both clinical and patient's point of view. The operated area healed completely within 10 days with normal appearance of gingiva. The use of scalpel technique for depigmentation is simple, effective, and most economical as compared with other techniques, which require more advanced armamentarium. The scalpel surgical technique leads to unpleasant bleeding during and after the procedure; hence, it is necessary to cover the surgical site (lamina

propria) with periodontal dressing for 7 to 10 days.<sup>8</sup> Even though the repigmentation is a common problem,<sup>9</sup> this scalpel surgical technique is highly recommended in the Indian population considering patient affordability and more predictable esthetically pleasing results.<sup>8</sup>

## CONCLUSION

Scalpel technique of surgical depigmentation procedure was successful and the patient was satisfied with the result. Treatment of gingival hyperpigmentation with scalpel technique is a very reliable, relatively simple, and cost-effective procedure by which highly predictable and esthetically pleasing results can be achieved with comparatively less discomfort to patient.

## REFERENCES

1. Tal H, Oegiesser D, Tal M. Gingival depigmentation by Erbium: YAG laser: clinical observations and patients responses. *J Periodontol* 2003 Nov;74(11):1660-1667.
2. Sanadi R, Suthar N, Bhusari BM, Chelani L. Gingival depigmentation using scalpel technique versus Laser technique: a case report. *IOSR J Dent Med Sci* 2015 Aug;14(8):38-40.
3. Cicek Y. The normal and pathological pigmentation of oral mucous membrane: a review. *J Contemp Dent Pract* 2003 Aug 15;4(3):76-86.
4. Dummett CO. Overview of normal oral pigmentations. *J Indiana Dent Assoc* 1980 May-Jun;59(3):13-18.
5. Dummett CO, Sakumura JS, Barends G. The relationship of facial skin complexion to oral mucosa pigmentation and tooth color. *J Prosthet Dent* 1980 Apr;43(4):392-396.
6. Tal H, Landsberg J, Koztovsky A. Cryosurgical depigmentation of the gingiva: a case report. *J Clin Periodontol* 1987 Nov;14(10): 614-617.
7. Roshna T, Nandakumar K. Anterior esthetic gingival depigmentation and crown lengthening: report of a case. *J Contemp Dent Pract* 2005 Aug 15;6(3):139-147.
8. Almas K, Sadig W. Surgical treatment of melanin pigmented gingiva: an esthetic approach. *Indian J Dent Res* 2002 Apr-Jun;13(2):70-73.
9. Verma S, Gohil M, Rathwa V. Gingival depigmentation. *Indian J Clin Pract* 2013 May;23(12):801-803.