

RESEARCH ARTICLE

Comparison of Two Radiographic Techniques in eliminating Zygomatic Buttress over Maxillary Molars in Children

¹Krishna Shah, ²Anupkumar Panda, ³Manpreet Kaur, ⁴Natasha Shiggaon, ⁵Krishna Dere, ⁶Mira Virda

ABSTRACT

Introduction: An ideal radiograph is one which has desired density and overall blackness and which shows the part completely without distortion with maximum details and has the right amount of contrast to make the details fully apparent. An image on radiograph is a two-dimensional representation of a three-dimensional object. They help to evaluate the success or failure of endodontic treatment. Image superimposition is a part of two-dimensional radiography. The radiographic superimposition of apical anatomical structures, especially zygomatic buttress on roots of maxillary molars, is common in bisecting angle technique (BAT), which affects the outcome of endodontic therapy in children. Angle reduction modification is carried out in BAT to minimize such image superimposition.

Aim and objective: The aim of this study was to compare two techniques of periapical radiography—BAT and modified bisecting angle technique (MBAT)—in preventing zygomatic superimposition over apices of maxillary young permanent molars.

Materials and methods: A total of 30 patients aged between 9 and 13 years requiring endodontic treatment for at least one maxillary molar were included in this study. First maxillary molar from every patient was subjected to two periapical radiographs, one with each BAT and MBAT respectively, giving a total of 60 radiographs. Each radiograph was recorded as acceptable or unacceptable, based on zygomatic superimposition and different technical aspects.

Results: The acceptability with MBAT was 86.7% (n = 26), while in BAT it was 56.7% (n = 17). The results of these two techniques were, therefore, statistically significant.

Keywords: Bisecting angle technique, Intraoral periapical techniques in children, Modified bisecting angle technique, Zygomatic buttress.

How to cite this article: Shah K, Panda A, Kaur M, Shiggaon N, Dere K, Virda M. Comparison of Two Radiographic Techniques in eliminating Zygomatic Buttress over Maxillary Molars in Children. *Int J Oral Care Res* 2017;5(3):224-228.

Source of support: Nil

Conflict of interest: None

¹Postgraduate Student, ²Head, ³⁻⁵Reader, ⁶Senior Lecturer

¹⁻⁶College of Dental Sciences and Research Centre, Ahmedabad Gujarat, India

Corresponding Author: Krishna Shah, Postgraduate Student College of Dental Sciences and Research Centre, Ahmedabad Gujarat, India, e-mail: Shahkrishna13303@gmail.com

INTRODUCTION

Radiographic examination is one of the primary diagnostic tools used in dentistry to determine a disease state and to formulate an appropriate treatment plan.¹ Intraoral radiographic examinations are the backbone of imaging for the dentist.

An intraoral periapical (IOPA) radiograph is the most frequently used radiograph in dental practice for viewing the tooth anatomy and its surrounding bone structure. Several abnormalities are diagnosed with the help of radiographs.² In addition to root canal morphology and periapical region, clinicians should be aware of the relationship of the teeth to their surrounding anatomical structures.

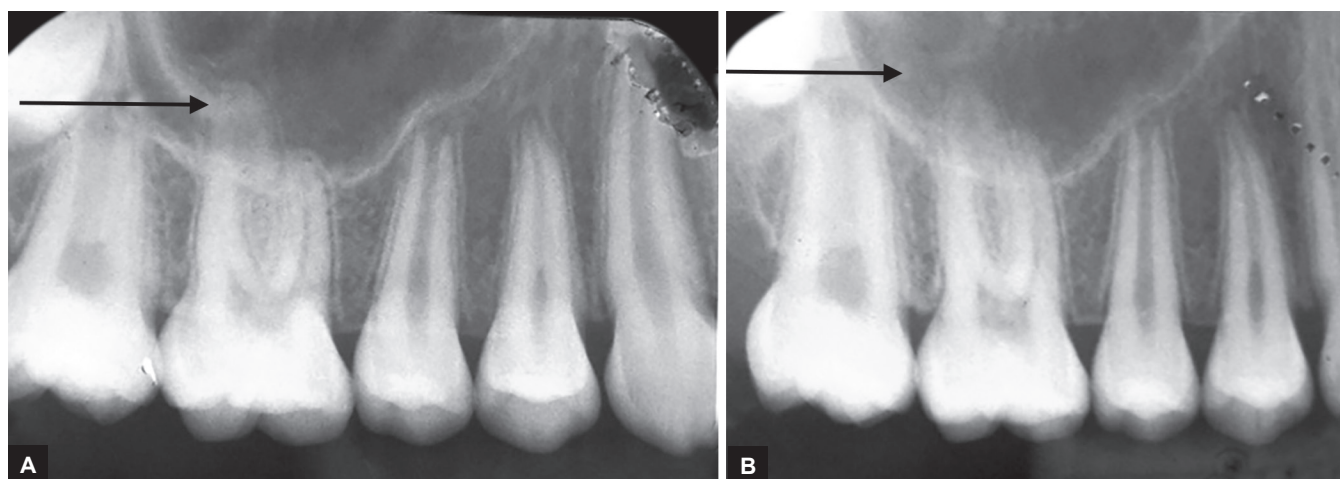
A radiograph is made with stationary X-ray source and displays a two-dimensional image of a part of the body.

The principles of projection geometry describe the effect of focal spot size and relative position of the object and image receptor on image clarity, magnification, and distortion.

The major anatomic considerations during endodontic treatment involve the incisive foramen, the maxillary sinus, and the zygomatic process of maxilla. The zygomatic process of the maxilla is an extension of the lateral maxillary surface that arises in the region of the apices of the first and second molars and serves as the articulation for the zygomatic bone. It appears as a U-shaped radiopaque line with rounded ends projected in the apical region of the first and second molars.³

The quality of radiographic image is not just determined by the anatomical landmarks but also by the direction of the X-ray beam. Due to a different projection angle of the X-ray beam, anatomical structures can be displaced relative to each other.⁴ The radiographic superimposition of apical anatomical structures, especially zygomatic buttress, on roots of maxillary molars is common in bisecting angle technique (BAT), which affects the outcome of the endodontic treatment in young permanent teeth. Angle reduction modification was carried out in BAT to minimize such image superimposition⁵ (Fig. 1).

The root formation and apex closure of young permanent teeth is important for treatment outcome. Apex of



Figs 1A and B : Angle reduction modification: (A) Bisecting angle technique; and (B) modified bisecting angle technique

young permanent molar is seen close to the zygomatic buttress and can be superimposed by zygomatic buttress on radiographs, due to which in apex of young permanent teeth, canals cannot be seen clearly.

AIM AND OBJECTIVE

To determine the application of modified bisecting angle technique (MBAT) and to compare MBAT with conventional BAT in preventing zygomatic buttress superimposition on periapical radiographs of maxillary young permanent molars useful for endodontic treatment.

MATERIALS AND METHODS

In this cross-sectional comparative study, a total of 30 patients aged between 9 and 13 years requiring endodontic treatment of at least one maxillary young permanent molar were included. Patients with incomplete root apex were not selected. First maxillary molar from every patient was subjected to two periapical radiographs, one with each BAT and MBAT respectively, giving a total of 60 radiographs. Each radiograph was recorded as acceptable (A) or unacceptable (UA), based on zygomatic superimposition and different technical aspects (Table 1). This study followed the ethical standards of the committee on human experimentation of the institution. All patients gave informed written consent to participate in this study.

Radiographic Techniques

The basic principle of MBAT is same as the conventional technique of bisecting the angle, i.e., Cieszynski's rule of isometry. The angle formed between the plane of the film and the long axis of the tooth is bisected. The central rays of the beam are at right angles to this imaginary bisector. Using the geometrical principle of isometric triangles, the actual length of the tooth will be equal to its image length.

The main differences between MBAT and BAT are film position and vertical angulation.

Patient's head should be upright with sagittal plane vertical and occlusal plane horizontal.

- In MBAT, the apical edge of the film is at same position as in routine method, but the occlusal edge is placed around 10 mm away from the occlusopalatal line angle of the teeth to be radiographed.
- If the distance between the occlusal edge of the film and occlusolingual angle of the teeth is increased, then the vertical angulation will be lesser than that required for BAT.

Data Collection

Diagnostic radiographs were taken using both the radiographic techniques, namely BAT and MBAT, on the same tooth utilizing periapical films (Speed E; Eastman Kodak Co., Rochester, NY, USA). A single researcher took all the radiographs using the Snap-A ray film holder (Dentsply Rinn Co., India) for both techniques.

Data Analysis

Each radiograph was recorded as A or UA, based on zygomatic superimposition and technical aspects. Radiographs covering the entire tooth free from zygomatic superimposition and technical errors and at least 1 to 2 mm of periradicular bone were considered as A. If a film was rated UA, the reasons for errors were recorded. Zygomatic superimposition, periapical cutoff (apex not seen), and image distortion were the three reasons for UA, applicable for both techniques. Each patient was asked about tolerance of both techniques, and the response was recorded as tolerable or intolerable.

Table 1: Different film position and vertical angulations required in BAT and MBAT for periapical projection of maxillary molars

| Technique | Distance between the occlusal edge of film to occlusolingual line angle of tooth (mm) | Vertical angulation of aiming tube |
|-----------|---|------------------------------------|
| BAT | 0 | +25° |
| MBAT | 10 | +10° |

Table 2: Comparison of MBAT and BAT in preventing zygomatic superimposition and concerned technical errors

| Radiographic quality | MBAT n = 30 | BAT n = 30 |
|----------------------|-------------|------------|
| A | 26 (86.7%) | 17 (56.7%) |
| UA | 04 (13.3%) | 13 (43.3%) |

All radiographs were assessed by two pediatric dentists using a standard illumination source and a viewing box. Two techniques were compared in preventing zygomatic superimposition, concerned technical errors and patient’s tolerability.

Statistical Analysis

Statistical comparison of two techniques in terms of A and UA was performed using Chi-square test and p value was recorded.

RESULTS

With MBAT (n = 30), the UA was 13.3% (n = 04), while 13 out of 30 radiographs (43.3%) were repeated when BAT was applied.

Modified bisecting angle technique had lesser zygomatic superimposition [13.3% (n = 4)] than BAT [43.3% (n = 13)] (Table 2). Image distortion was also less in MBAT than BAT. The incidence of incomplete periapical image was higher in MBAT (20%) than BAT (10%). Patient comfort zone was almost similar in both techniques.

The distribution of various aspects of two techniques is shown in Graph 1. A statistically significant difference (p = 0.000) in preventing zygomatic superimposition was found between MBAT and BAT.

DISCUSSION

The anatomy of the mouth does not always allow rules of geometric projections to be satisfied.⁶ Bisecting angle

technique is routinely used in dental practice. It is relatively simple, quick, and patient comfortable,⁷ but has an inherent drawback of image distortion. Standard BAT has been modified for periapical views of incisor teeth and molar teeth.

The technique involves a constant X-ray cone position, which is perpendicular to the floor for maxillary incisors and parallel to the floor for mandibular incisors. The periapical film is held between the incisor teeth as if it were an occlusal film for all anterior periapical radiographs.⁸

For the posterior region, the angle has to be formed between the receptor and the teeth in modified method and it should be lower than the BAT. Palatal anatomy guides the distance between the film and the teeth, i.e., around 10 mm.⁵ This technique is suggested as an alternative to the standard BAT and the parallel technique.

It is intended for anterior periapical radiographs when clinical conditions make conventional techniques difficult. For example, it can be used in very young children, patients with gagging problems, and patients with narrow lower jaws or large muscular tongues.⁸

The image interference of zygomatic arch with the apical third of maxillary first molar has made BAT diagnostically unreliable in this region. Therefore, certain alterations were carried out in BAT, and then both techniques were compared in avoiding zygomatic superimposition⁵ (Fig. 2).

The MBAT can minimize disadvantages of BAT like foreshortening of the buccal roots of maxillary molars and shadowing of zygomatic buttress on roots of maxillary molars.

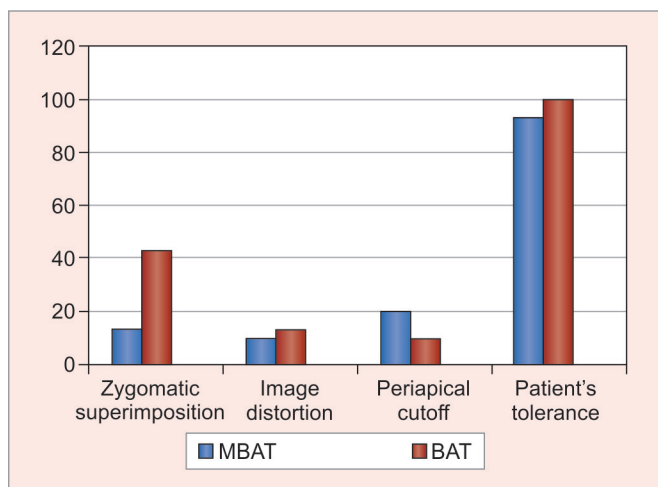
In the present study, BAT could not be able to separate roots and zygomatic arch in 43.3% of cases, while MBAT could not be able to separate roots and zygomatic arch in only 13.3% of cases.

According to Mahnaz et al,⁹ this separation was only 40% in BAT and MBAT had prevented zygomatic image superimposition in 73.8% cases, while in the present study image distortion was found to be nonsignificant between both techniques (MBAT = 10% and BAT = 13.5%).

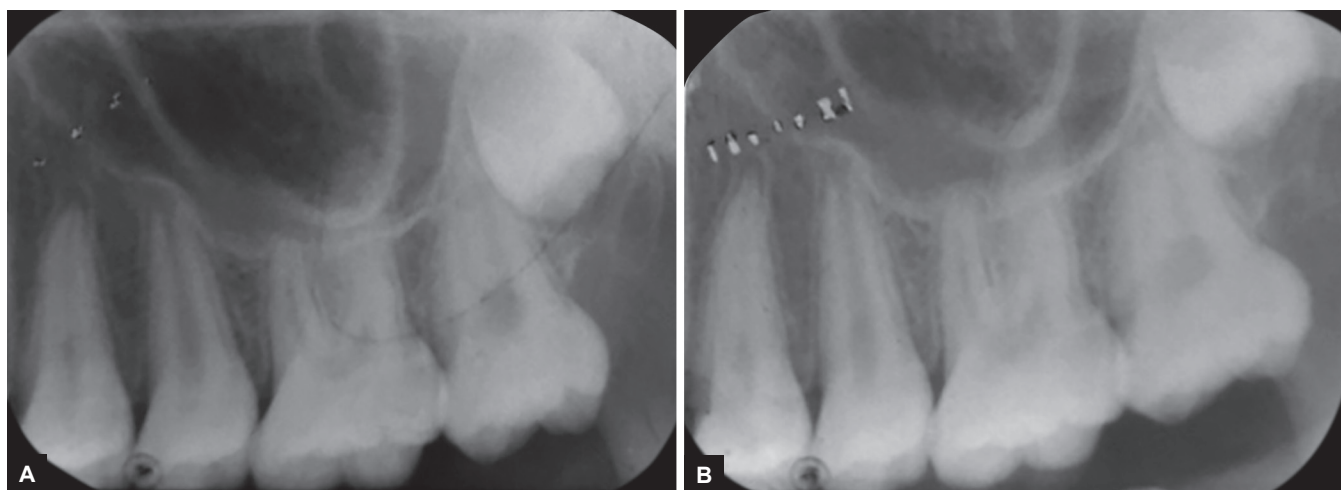
According to Jamdade,⁵ BAT was unable to separate roots and zygomatic arch in 56.5% of cases, while MBAT was unable to separate roots and zygomatic arch in only 17.7%.

Disadvantages of modified technique are apices of the teeth can sometimes appear near the apical edge of the film. Periapical cutoff (incomplete apical image) was higher in MBAT (20%) than BAT (10%) (Fig. 3).

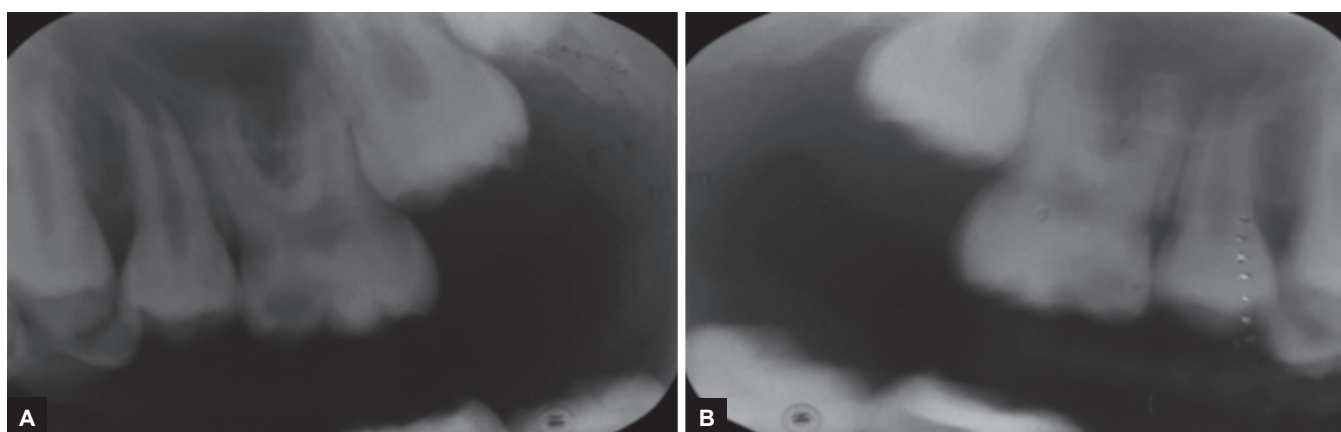
With MBAT, we can get better IOPA and eliminate superimposition of zygomatic arch on molar roots, which provide better diagnosis and evaluation after treatment (Fig. 4).



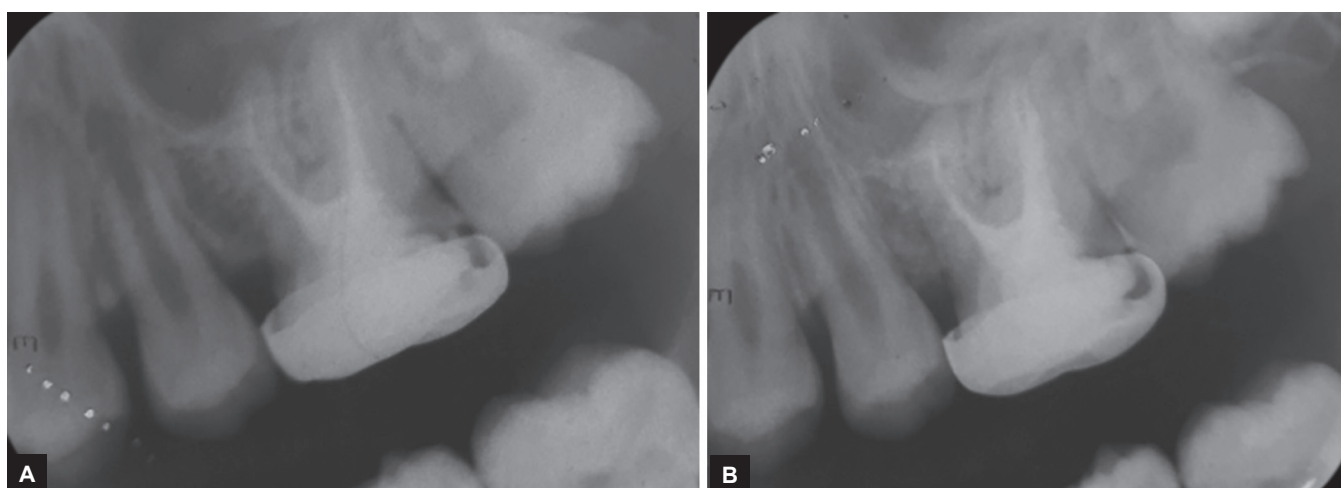
Graph 1: Distribution of different techniques of UA and patient's tolerability in the two techniques



Figs 2A and B: Periapical radiograph taken by BAT shows interference of zygomatic process and lower border of zygomatic arch over molars apices: (A) BAT; and (B) MBAT



Figs 3A and B: MBAT shows periapical image cut-off in molar region: (A) BAT; and (B) MBAT



Figs 4A and B: Comparison of MBAT and BAT after root canal treatment: (A) BAT; and (B) MBAT

CONCLUSION

Modified bisecting angle technique periapical radiography has high accuracy in preventing zygomatic superimposition over roots of maxillary molars than BAT radiography. Although the patient tolerance of BAT

was almost similar to that of MBAT, the MBAT is recommended for periapical radiography of maxillary molars. Pedodontists treat the young permanent teeth and the root formation and apex closure of young permanent teeth is important for treatment outcome.¹⁰⁻¹²

REFERENCES

1. Walton, RE. Endodontic radiography. In: Torabinejad M, Walton RE, editors. Endodontics: principles and practice. 4th ed. St. Louis (MO): Saunders Elsevier; 2009.
2. Whaites, E. Essentials of dental radiography and radiology. 3rd ed. In: Periapical radiography. Edinburgh: Churchill Livingstone; 2002. pp. 92.
3. Karjodkar, FR. Essentials of oral & maxillofacial radiology. 1st ed. New Delhi: Jaypee; 2014. pp. 199-218.
4. Ghom, AG.; Ghom, SA. Text book of oral radiology. 2nd ed. In: Patil K, Patil M, editors. Chapter 21: principle of radiographic interpretation. New Delhi: Elsevier; 2008. pp. 269-277.
5. Jamdade AS. Modified bisecting angle technique in eliminating zygomatic superimposition over apices of maxillary molars. Indian J Dent Res 2014 Oct;25(4):521-526.
6. Bean LR. Comparison of bisecting angle and paralleling methods of intraoral radiology. J Dent Educ 1969 Dec;33(4):441-445.
7. White, S.; Pharoah, M. Oral radiology principles and interpretation. 6th ed. St. Louis (MO): Mosby; 2009. pp. 109-135.
8. Monsour PA. A modification of the bisecting-angle technique for anterior periapical dental radiographs. Oral Sur Oral Med Oral Pathol 1986 Oct;62(4):468-470.
9. Mahnaz S, Reza Z, Vida M. Comparison of three periapical techniques in distinguishing the roots of maxillary second molars and preventing superimposition with zygomatic arch. J Isfahan Dent Sch 2012 Aug;8(3):229-234.
10. Espelid, I.; Mejàre, I.; Weerheijm, K. EAPD guidelines for use of radiographs in children. Eur J Paediatr Dent 2003 Mar;4(1): 40-48.
11. Tamse A, Kaffe I, Fishel D. Zygomatic arch interference with correct radiographic diagnosis in maxillary molar endodontics. Oral Surg Oral Med Oral Pathol 1980 Dec;50(6): 563-566.
12. Sansare K, Khanna V, Karjodkar F. Early victims of X-rays: a tribute and current perception. Dentomaxillofac Radiol 2011 Feb;40(2):123-125.