

Comparative Evaluation of Platelet-rich Fibrin with Metformin and Platelet-rich Fibrin Alone in the Treatment of Intrabony Periodontal Defects: A Clinical and Radiographical Study

¹Neha Taneja, ²Praveen B Kudva, ³Hema P Kudva

ABSTRACT

Aim: The study comparatively evaluated the efficacy of platelet-rich fibrin (PRF) with metformin (MTF) and PRF alone in the treatment of intrabony periodontal defects both clinically and radiographically.

Materials and methods: A total of 20 subjects maintaining good oral hygiene with minimum two sites having vertical bony defects were selected using cone beam computed tomography (CBCT). All subjects were randomly assigned to any one of the two groups (group I: PRF + MTF; group II: PRF only) using lottery system.

All subjects underwent open flap debridement (OFD) and placement of either of the materials mentioned above and a periodic follow-up at 6 and 9 months.

Results: Improvement in clinical parameters [plaque index, gingival index, probing depth (PD), relative attachment level (RAL)] as well as in radiographic parameters (defect depth and defect volume) as compared with baseline in both the groups was observed, with group I exhibiting higher statistically significant values as compared with group II.

Conclusion: The combination of PRF + MTF was proven to be better than PRF alone. Further, long-term clinical trials with larger samples of various drug concentrations and longer durations should be carried out to assess a complete periodontal regeneration rather than bone regeneration.

Keywords: Chronic periodontitis, Endogenous regenerative technology, Intrabony defects, Metformin, Platelet-rich fibrin.

How to cite this article: Taneja N, Kudva PB, Kudva HP. Comparative Evaluation of Platelet-rich Fibrin with Metformin and Platelet-rich Fibrin Alone in the Treatment of Intrabony Periodontal Defects: A Clinical and Radiographical Study. Int J Oral Care Res 2017;5(3):178-186.

Source of support: Nil

Conflict of interest: None

¹Postgraduate Student, ²Professor and Head, ³Reader

^{1,2}Department of Periodontology and Oral Implantology, Jaipur Dental College, Jaipur, Rajasthan, India

³Department of Anatomy, Jaipur Dental College, Jaipur Rajasthan, India

Corresponding Author: Neha Taneja, Postgraduate Student Department of Periodontology and Oral Implantology, Jaipur Dental College, Jaipur, Rajasthan, India, Phone: +919828268896 e-mail: hemprakudva@gmail.com

INTRODUCTION

Periodontitis is considered as “an inflammatory disease of the supporting tissues of the teeth.”¹ Chronic periodontitis is considered as the most common form of periodontitis, which is further classified as localized or generalized (more than 30% of the sites) depending on the site involvement.

Various treatment modalities have been advocated in the treatment of periodontitis with an objective of maintenance of the natural dentition in a healthy state and allowing for proper function.

Presently, endogenous regenerative technology (ERT) has gained attention in the field of regeneration as it can trigger latent self-repair mechanisms in patients and activate the host’s innate capacity for regeneration.

The most widely used ERT is PRF. The PRF, a second-generation platelet concentrate,² is an autologous leukocyte and PRF biomaterial as described by Choukroun.³⁻⁵ It is made up of an integrated conclave of cytokines, glycanic chains, and structural glycoproteins encased within a slowly polymerized fibrin network.

Currently, drugs have also been incorporated into ERT to create a material alcove in an injured site where the progenitor/stem cells from neighboring tissues can be employed for *in situ* periodontal regeneration.

Metformin acts at a cellular level by reducing intracellular reactive oxygen species and apoptosis and exhibits a direct osteogenic effect on osteoblasts. The osteogenic effect is due to insulin-like growth factor-1 expression⁶ and partially mediated via promotion of Runx2. Further, it can induce MC3T3E1 osteoblastic cell differentiation and bone matrix synthesis through adenosine 5’ monophosphate-activated protein kinase activation and subsequent induction of endothelial nitric oxide synthase and bone morphogenetic protein 2 expression. Hence, MTF is a drug of interest for the periodontist for treating periodontitis-induced alveolar bone loss.

The detection and accurate assessment of the location, extent, and configuration of the intrabony defect were done using CBCT as it is an enhanced tool to assess endosseous defect correctly.

The present study is an effort to comparatively evaluate the efficacy of PRF with MTF and PRF alone in the treatment of intra-bony periodontal defects both clinically and radiographically.

The study was conducted at the Department of Periodontology and Oral Implantology, Jaipur Dental College, Jaipur, Rajasthan, India. The proposed study began after the approval from the Institutional Research Review Board, Jaipur Dental College, Jaipur. Informed consent was taken from the subjects participating in the study.

MATERIALS AND METHODS

Subjects following a maintenance phase were recalled for periodontal assessment. A total of 20 subjects maintaining good oral hygiene with a minimum of two sites having vertical bony defects were selected. All subjects were randomly assigned to any one of the following groups using lottery system:

Group I—OFD followed by placement of PRF with MTF 1% gel.

Group II—OFD followed by placement of PRF alone

Inclusion Criteria

Subjects in the age range of 35 to 55 years with systemically healthy status and pocket PD in the range of 5 to 7 mm, bilateral intra-bony vertical defects, and radiographic evidence of vertical bone loss were included in the study.

Exclusion Criteria

Subjects with medically compromised status (history of diabetes, hypertension, thyroid), pregnant females or lactating mothers, subjects allergic to any type of medications, smokers, patient with unacceptable oral hygiene, and periodontal resurgical cases were excluded from the study.

Materials used in the Study

- Platelet-rich fibrin—A blood sample was taken without anticoagulant in 10 mL tubes, which were immediately centrifuged at 3,000 rpm (approximately 400g according to our calculations) for 10 minutes. This technique required neither anticoagulant nor bovine thrombin (nor any other gelling agent).²
- Metformin—A 1% MTF gel developed as dry gellan gum powder was dispersed in distilled water maintained at 95°C. The dispersion was stirred at 95°C for 20 minutes using a magnetic stirrer to facilitate hydration of gellan gum. The required amount of mannitol was added to the gellan gum solution with continuous stirring, and the temperature was maintained above 80°C. A weighed amount of MTF was added with stirring. Then sucralose, citric acid, and

preservatives (methylparaben, propylparaben) were added with stirring. Finally, the required amount of sodium citrate was dissolved in 10 mL distilled water and added to the mixture. The mixture was allowed to cool to room temperature to form a gel.⁷

Storage and Shelf Life

The MTF gel was stored in a refrigerator at a temperature of 10 to 18°C and had a shelf life up to December 15, 2017.

In vitro Studies (Diffusion Cell)

The *in vitro* study part was carried out at Sree Dattha Institute of Pharmacy, Hyderabad, India.

Presurgical Phase

All subjects received scaling and root planing (SRP) followed by oral hygiene instructions. All patient underwent radiovisiography followed by CBCT for locating bony defects. Customized acrylic stent using cold-cure acrylic resins was prepared on the stone models by making alginate impressions of the subjects.

Clinical Parameters

All clinical parameters were recorded preoperatively (baseline recordings), at 6 and 9 months postoperatively. A stent was used along with a calibrated probe (UNC 15 probe) to ensure reliability and reproducibility of data collected sequentially. Clinical parameters recorded were plaque index, gingival index, PD, and RAL.

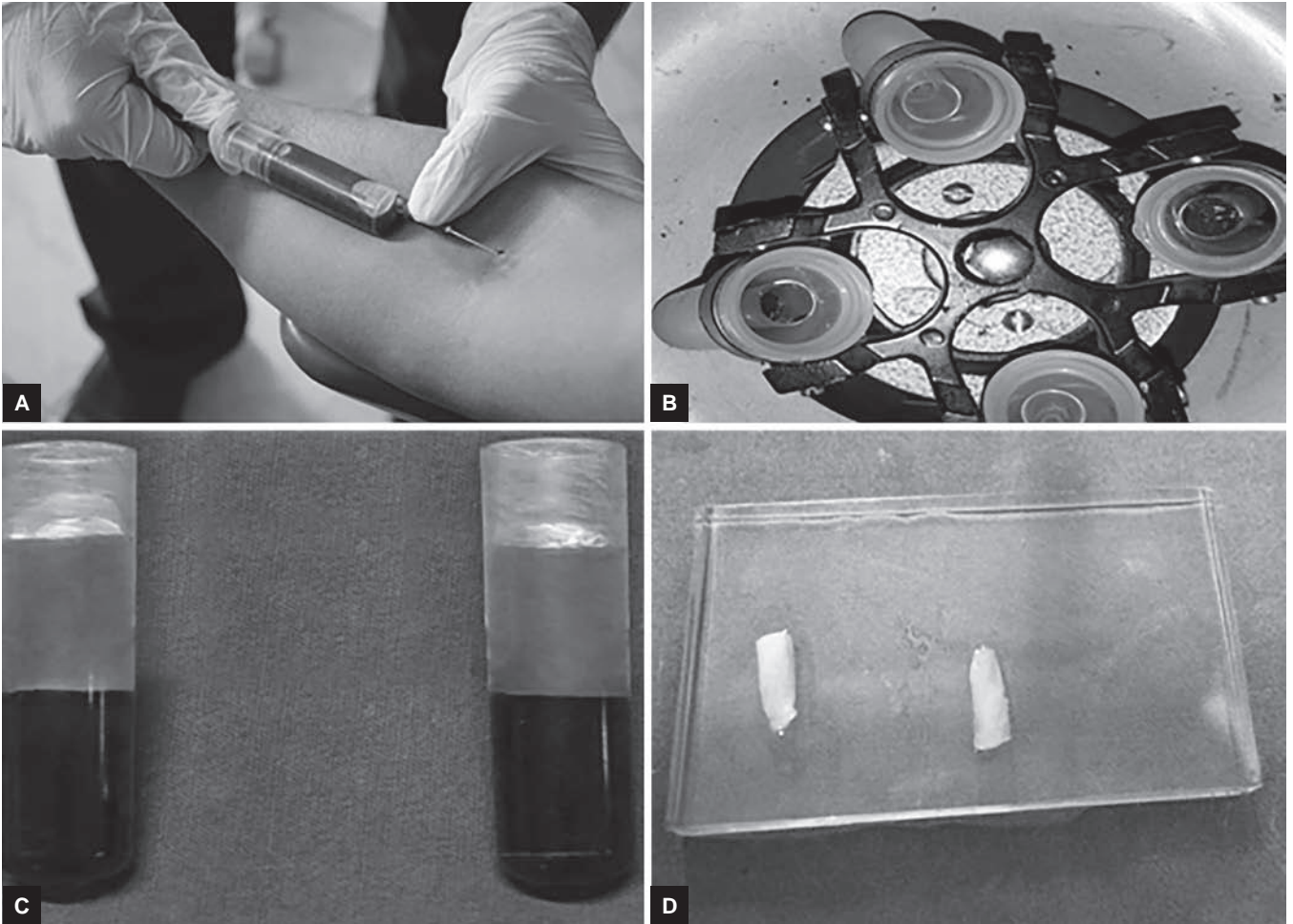
Bone defect morphology was assessed using three-dimensional (3D) CBCT (version 3.5.7; Carestream Health, Inc., New York, USA) with the following parameters: Slice thickness of 0.625 mm, exposure of 68 to 90 KVP, and 4 mA. It is a high-resolution CT scanner equipped with a 3D image reconstruction software (Carestream CS9300 imaging system imaging) For clinical procedure kindly refer (Figs 1 to 10).

Statistical Analysis


The data were coded and entered into a Microsoft Excel spreadsheet. Analysis was done using Statistical Package for the Social Sciences version 20 (IBM SPSS Statistics Inc., Chicago, Illinois, USA) Windows software program. The variables were assessed for normality using the Kolmogorov–Smirnov test. Descriptive statistics included computation of percentages, means, and standard deviations.

RESULTS

Upon intragroup comparison for soft tissue parameters in group I (PRF + MTF), the mean values of plaque index



Figs 1A to D: Platelet-rich fibrin preparation



Figs 2A and B: (A) 1% MTF; and (B) 1% MTF mixed with PRF

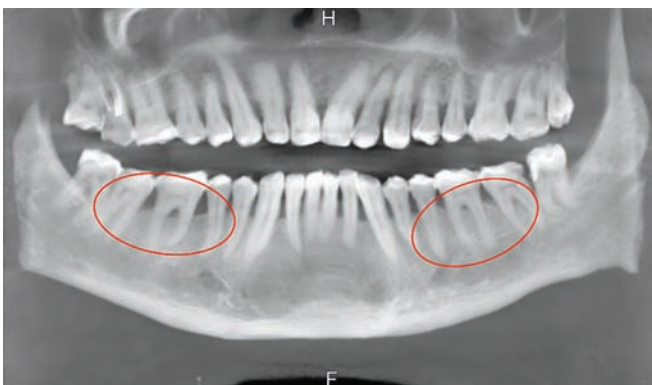


Fig. 3: Preoperative CBCT (panoramic view)

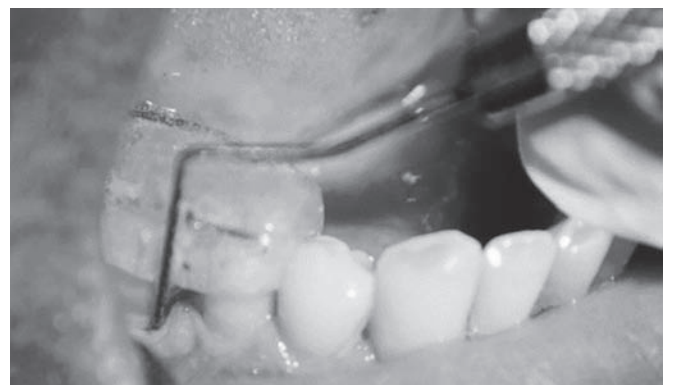

Fig. 4: Preoperative RAL measurements

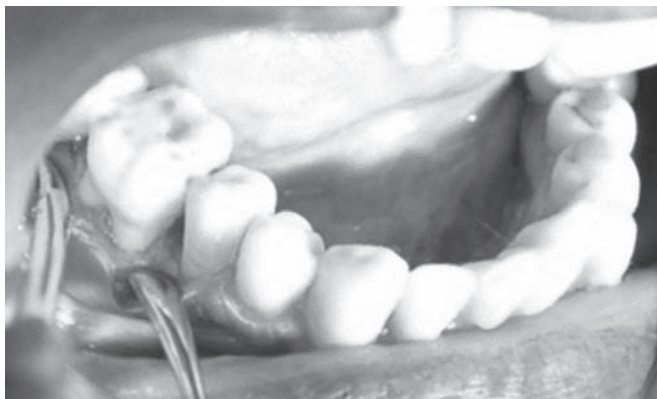

Fig. 5: Mucoperiosteal flap reflection

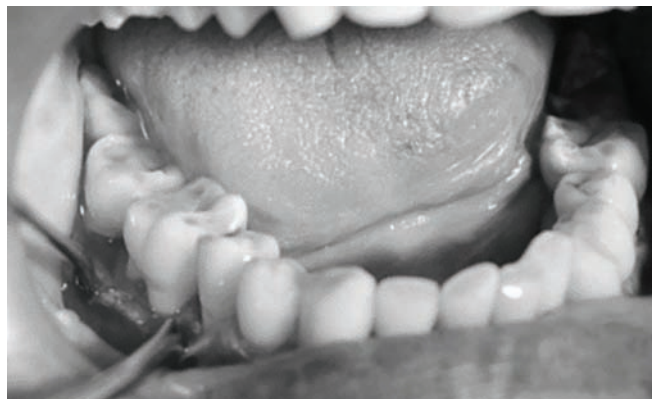


Fig. 6: Defect site

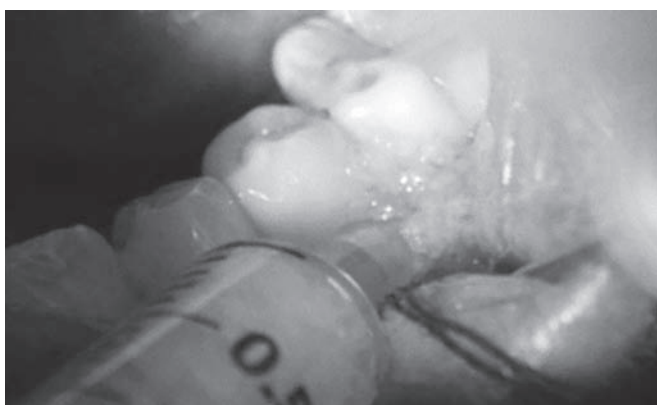


Fig. 7: Placement of 1% MTF (group II)

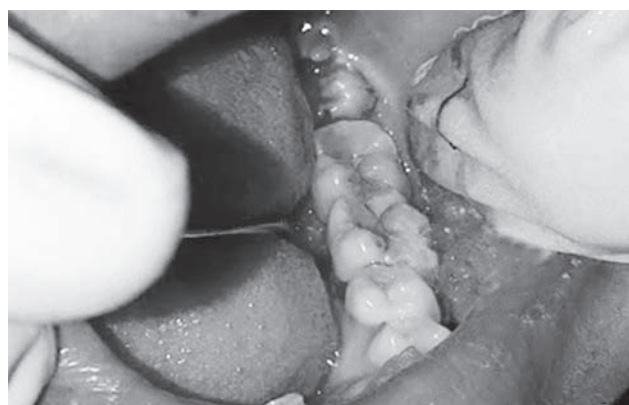

Fig. 8: Placement of PRF (group II)

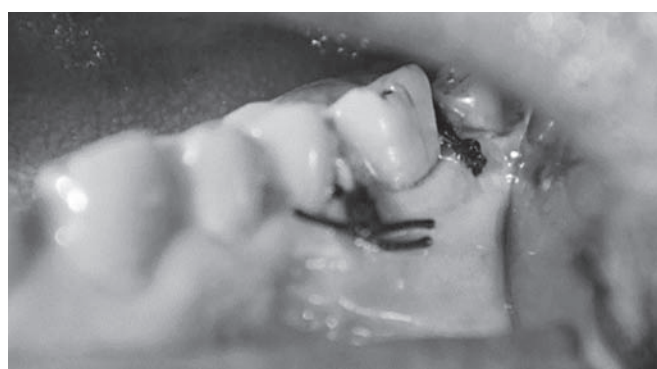

Fig. 9: Sutures

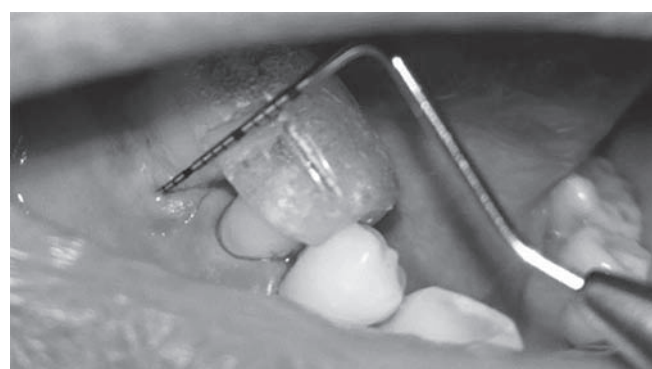


Fig. 10: Postoperative RAL measurement

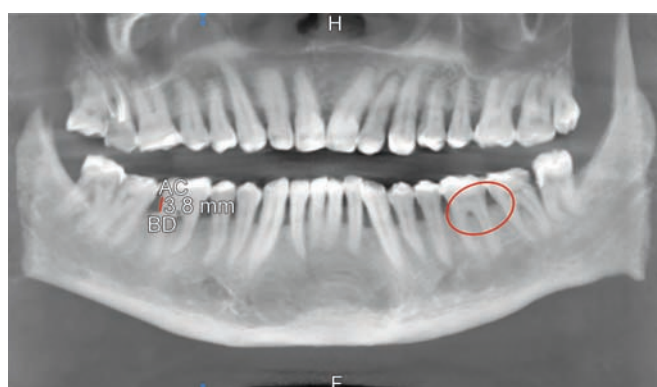
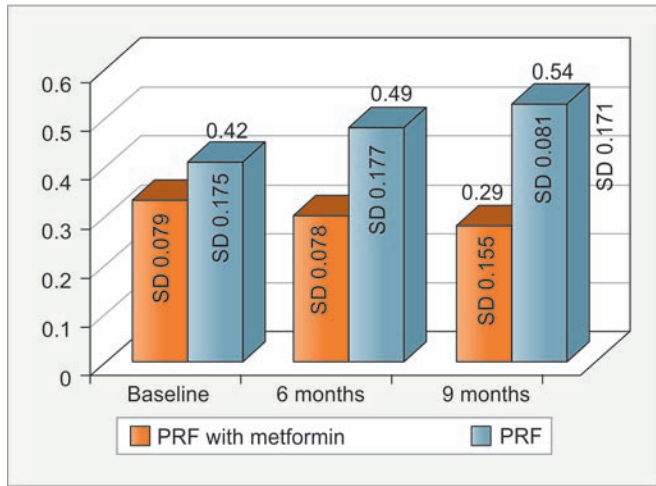


Fig. 11: Postoperative CBCT (panoramic view)

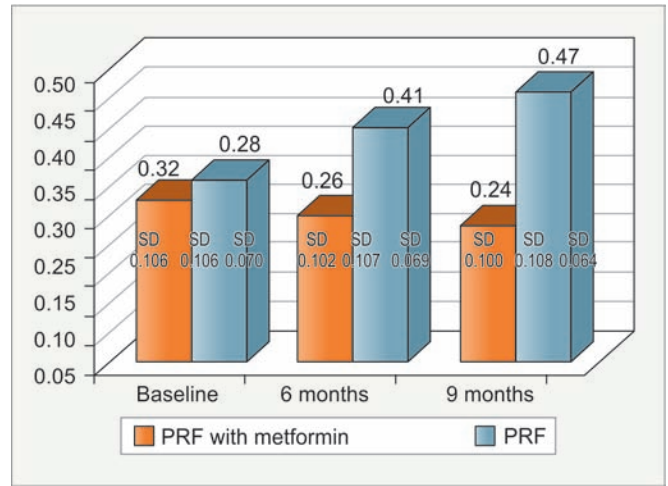
and gingival index (Graphs 1 and 2) at 6 and 9 months from baseline were found to be nonsignificant. Comparison of change between 6 and 9 months revealed a nonsignificant change.

The mean values of PD and RAL (Graphs 3 and 4) at 6 and 9 months from baseline were found to be significant. Comparison of change between 6 and 9 months revealed a significant change.

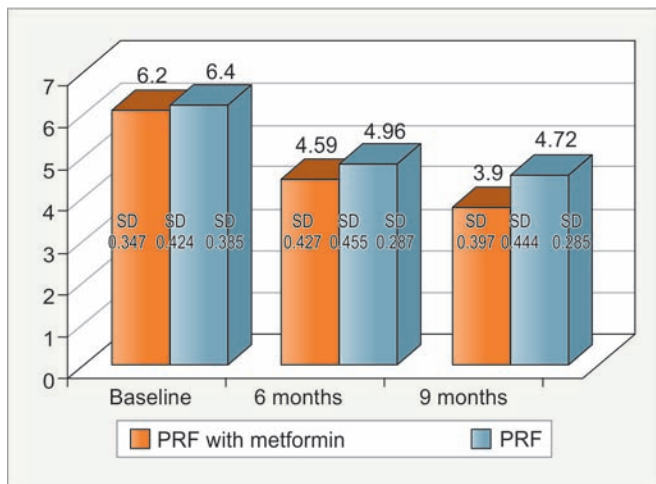
In group II PRF, the mean values of plaque index at 6 and 9 months from baseline were found to be nonsignificant. Comparison of change between 6 and 9 months revealed a nonsignificant change.



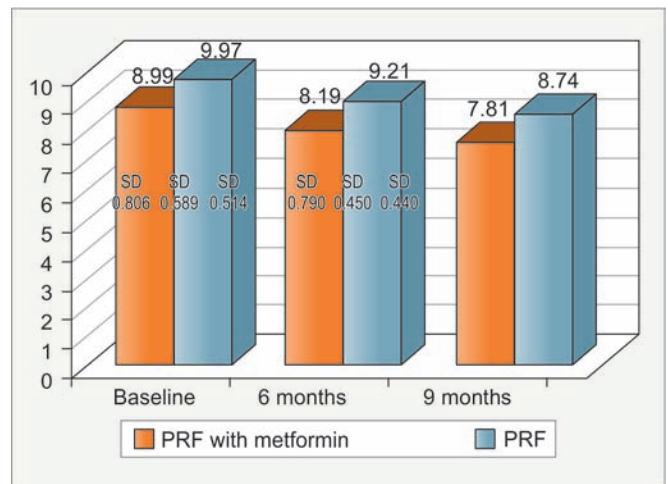
Graph 1: Mean plaque index at various time intervals of both the groups. SD: Standard deviation



Graph 2: Mean gingival index at various time intervals of both the groups



Graph 3: Mean PD at various time intervals of both the groups



Graph 4: Mean RAL at various time intervals of both the groups

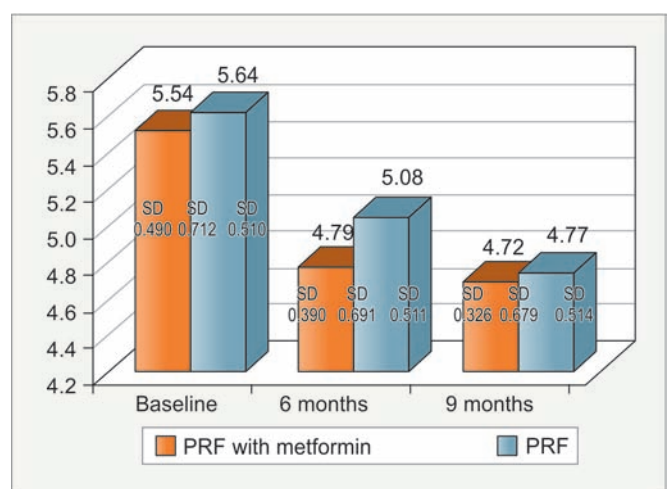
The mean values of gingival index at 6 and 9 months from baseline were found to be significant. Comparison of change between 6 and 9 months revealed a nonsignificant change.

The mean values of PD and RAL at 6 and 9 months from baseline were found to be significant. Comparison of change between 6 and 9 months revealed a nonsignificant change.

Considering hard tissue parameters in group I (PRF + MTF), the mean value of defect depth at 6 months from baseline was found to be nonsignificant and 9 months from baseline was found to be significant. Comparison of change between 6 and 9 months revealed a nonsignificant change.

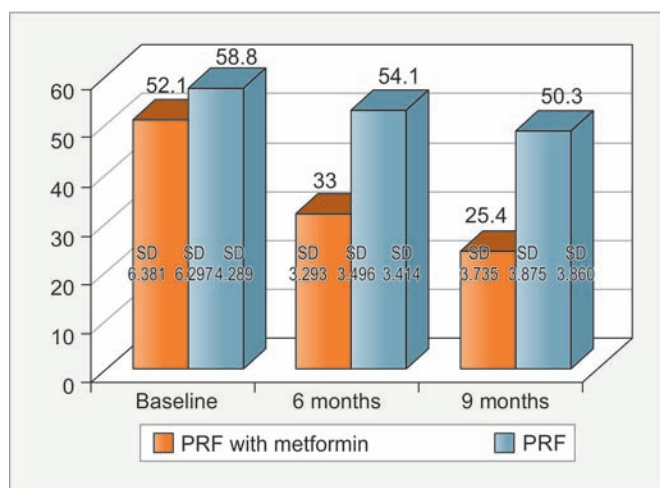
The mean value of defect volume at 6 and 9 months from baseline was found to be significant. Comparison of change between 6 and 9 months revealed a significant change.

In group II PRF, the mean value of defect depth at (Graph 5) 6 months from baseline was found to be



Graph 5: Mean defect depth at various time intervals of both the groups

nonsignificant and at 9 months from baseline was found to be significant. Comparison of change between 6 and 9 months revealed a nonsignificant change.



Graph 6: Mean defect volume at various time intervals of both the groups

The mean value of defect volume (Graph 6) at 6 and 9 months from baseline was found to be significant. Comparison of change between 6 and 9 months revealed a significant change.

Table 1: Comparison of plaque index

			Mean difference	p-value
Platelet-rich fibrin with metformin	Baseline	6 months	0.026	1.000
		9 months	0.048	0.571
		6 months	-0.026	1.000
	6 months	Baseline	0.022	1.000
		9 months	-0.048	0.571
		6 months	-0.022	1.000
Platelet-rich fibrin	Baseline	6 months	-0.077	0.999
		9 months	-0.124	0.372
		6 months	0.077	0.999
	6 months	Baseline	-0.047	1.000
		9 months	0.124	0.372
		6 months	0.047	1.000

Intragroup comparisons at various time intervals

Table 3: Comparison of PD

			Mean difference	p-value
Platelet-rich fibrin with metformin	Baseline	6 months	1.61	0.000 (S)
		9 months	2.1	0.000 (S)
		6 months	-1.61	0.000 (S)
	6 months	Baseline	0.49	0.05 (S)
		9 months	-2.1	0.000 (S)
		6 months	-0.49	0.05 (S)
Platelet-rich fibrin	Baseline	6 months	1.44	0.000 (S)
		9 months	1.68	0.000 (S)
		6 months	-1.44	0.000 (S)
	6 months	Baseline	0.24	0.325
		9 months	-1.68	0.000 (S)
		6 months	-0.24	0.325

Intragroup comparisons at various time intervals; S: Significant

Upon intergroup comparison for mean plaque index scores, the mean difference from baseline to 6 months was nonsignificant. Mean difference from baseline to 9 months was found to be nonsignificant (Table 1).

Mean gingival index score from baseline to 6 months was found to be nonsignificant in group I, while in group II it was found to be significant ($p \leq 0.05$). Mean difference from baseline to 9 months was found to be nonsignificant in group I, while in group II, it was found to be significant ($p \leq 0.05$) (Table 2).

Mean PD score from baseline to 6 months was found to be significant in all groups ($p \leq 0.05$) (Table 3). Mean difference from baseline to 9 months was found to be significant in all groups ($p \leq 0.05$).

Mean RAL score from baseline to 6 months was found to be significant in both the groups ($p \leq 0.05$). Mean difference from baseline to 9 months was found to be significant in both the groups ($p \leq 0.05$) (Table 4).

Mean defect depth score from baseline to 6 months was found to be significant in group I ($p \leq 0.05$), while it was nonsignificant in group II. Mean difference from

Table 2: Comparison of gingival index

			Mean difference	p-value
Platelet-rich fibrin with metformin	Baseline	6 months	0.02	1.000
		9 months	0.037	1.000
		6 months	-0.02	1.000
	6 months	Baseline	0.017	1.000
		9 months	-0.037	1.000
		6 months	-0.017	1.000
Platelet-rich fibrin	Baseline	6 months	-0.088	0.02 (S)
		9 months	-0.145	0.000 (S)
		6 months	0.088	0.02 (S)
	6 months	Baseline	-0.057	0.217
		9 months	0.145	0.000 (S)
		6 months	0.057	0.217

Intragroup comparisons at various time intervals; S: Significant

Table 4: Comparison of RAL

			Mean difference	p-value
Platelet-rich fibrin with metformin	Baseline	6 months	0.8	0.005 (S)
		9 months	1.18	0.001 (S)
		6 months	-0.8	0.005 (S)
	6 months	Baseline	0.38	0.32
		9 months	-1.18	0.001 (S)
		6 months	-0.38	0.32
Platelet-rich fibrin	Baseline	6 months	0.76	0.003 (S)
		9 months	1.23	0.000 (S)
		6 months	-0.76	0.003 (S)
	6 months	Baseline	0.47	0.094
		9 months	-1.23	0.000 (S)
		6 months	-0.47	0.094

Intragroup comparisons at various time intervals; S: Significant

Table 5: Comparison of defect depth

			Mean difference	p-value
Platelet-rich fibrin with metformin	Baseline	6 months	0.35	0.05 (S)
		9 months	0.82	0.04 (S)
	6 months	Baseline	-0.55	0.264
		9 months	0.27	1.000
	9 months	Baseline	-0.82	0.04 (S)
		6 months	-0.27	1.000
Platelet-rich fibrin	Baseline	6 months	0.56	0.064
		9 months	0.89	0.002 (S)
	6 months	Baseline	-0.56	0.064
		9 months	0.33	0.484
	9 months	Baseline	-0.89	0.002 (S)
		6 months	-0.33	0.484

Intragroup comparisons at various time intervals; S: Significant

Table 6: Comparison of defect volume

			Mean difference	p-value
Platelet-rich fibrin with metformin	Baseline	6 months	19.10	0.000 (S)
		9 months	26.70	0.000 (S)
	6 months	Baseline	-19.10	0.000 (S)
		9 months	7.60	0.002 (S)
	9 months	Baseline	-26.70	0.000 (S)
		6 months	-7.60	0.002 (S)
Platelet-rich fibrin	Baseline	6 months	4.7	0.02 (S)
		9 months	8.5	0.000 (S)
	6 months	Baseline	-4.7	0.02 (S)
		9 months	3.8	0.07
	9 months	Baseline	-8.5	0.000 (S)
		6 months	-3.8	0.07

Intragroup comparisons at various time intervals; S: Significant

baseline to 9 months was found to be significant in both the groups ($p \leq 0.05$) (Table 5).

Mean defect volume score from baseline to 6 months was found to be significant in all groups ($p \leq 0.05$). Mean difference from baseline to 9 months was found to be significant in both the groups ($p \leq 0.05$) (Table 6).

DISCUSSION

The present study was designed as a randomized controlled trial, which comprised 20 systemically healthy subjects having moderate-to-severe chronic generalized periodontitis with a minimum of two sites having intrabony defects (IBDs) totaling to 40 defect sites.

A comparative assessment of PRF with MTF and PRF alone in treatment of IBDs was done in the present study.

The clinical parameters assessed were plaque index; gingival index, PD, and RAL.

Plaque index and gingival index were recorded to assess the oral hygiene maintenance and inflammatory status at various time intervals. Probing depth and RAL were assessed to evaluate the outcome of various treatment modalities.

The CBCT was used for the study since it had various advantages over the conventional radiographic technique (intraoral periapical radiograph, orthopantomogram) such as display of multiple panoramic and cross-sectional images followed by generation in three types of views: Axial, cross-sectional, and panoramic.

The defects were randomly divided into two test groups using lottery method: Group I involved the use of PRF with MTF; group II involved the use of PRF only.

Presently, for periodontal regeneration, various chemical agents and growth factors have been advocated. The PRF has been used in different treatment modalities for root coverage and treating intrabony periodontal defects.

Drugs, such as MTF had shown to have other beneficial properties besides their main properties, such as osteogenic potential. Hence, in the present study, it was incorporated in PRF to assess their regeneration potential.

In the present study, the role of MTF when incorporated with PRF was evaluated when placed in an IBD.

The MTF, a biguanide compound, is widely prescribed as the first-line antidiabetic agent for the treatment of type II diabetes mellitus as it is an insulin-sensitizing drug, lowering glycemic level without increasing insulin secretion. In the field of periodontology, it has been studied for its effect to reduce inflammatory cell infiltration and alveolar bone loss in periodontal tissue. It can be given either with a systemic administration or with local biodegradable sustained-release agents (gels, chips, membranes).

The MTF has been shown to promote osteoblastic differentiation and increase collagen synthesis as per studies done by Cortizo et al.⁸ The study evaluated the effects of MTF on the growth and differentiation of osteoblasts in culture. The MTF also promoted osteoblastic differentiation: It increased type I collagen production in both cell lines and stimulated alkaline phosphatase activity in MC3T3E1 osteoblasts.

The results are in hand with the study by Pradeep et al⁹ who evaluated the efficacy of OFD combined with PRF, 1% MTF gel, and PRF + 1% MTF gel in the treatment of IBDs in patients with chronic periodontitis and concluded that the PRF + 1% MTF group showed greater improvements in clinical parameters, with greater percentage radiographic defect depth reduction compared with MTF, PRF, or OFD alone in treatment of intrabony defects in patients with chronic periodontitis.

The results are in agreement with a study done by Bak et al¹⁰ who stated MTF augmented the mineralization of MC3T3-E1 cells approximately twofold over the nontreated cells and suggested that MTF may exert a

beneficial effect on alveolar bone in periodontitis by increasing osteoblast differentiation.

The results are in accordance with the study done by Agarwal,¹¹ who stated that a possible bone-sparing and bone-formative effect of MTF has been postulated. The MTF has been shown to significantly decrease the intracellular reactive oxygen species and apoptosis and also have a direct osteogenic effect on osteoblasts, which could be partially mediated through promotion of Runx2 and insulin-like growth factor 1 expression.

The results are in accordance with the study by Pradeep et al,¹² who explored the efficacy of 0.5, 1, and 1.5% MTF gel as a local drug delivery system in adjunct to SRP for treatment of IBD in patients with chronic periodontitis. The study concluded that local delivery of MTF into the periodontal pocket stimulated significant increase in the PD reduction, clinical attachment level gain, and improved IBD depth reduction compared with placebo in adjunct to SRP.

The results of the present study are not in agreement with the study done by Jeyabalan et al,¹³ who concluded that MTF shows no adverse effects on bone mass and fracture healing in rodents, but demonstrates that MTF is not osteogenic *in vivo*.

In group II, PRF was used for treatment of IBDs. The PRF as described by Choukroun et al² allows one to obtain fibrin mesh enriched with platelets and growth factors, from an anticoagulant-free blood harvest without any artificial biochemical modification. The PRF clot forms a strong natural fibrin matrix, which concentrates almost all the platelets and growth factors of the blood harvest and shows complex architectures as a healing matrix, including mechanical properties, which no other platelet concentrate can offer. It also acts as an innovative growth factor delivery medium. It has been used in the field of periodontology since long either as a membrane or as a vehicle.

The results of the present study are in accordance with the study by Khiste and Tari,¹⁴ who focused on the properties and various applications of PRF in clinical practice. Wound healing is a staged process, which involves the activity of leukocytes and platelets. The growth factors present in platelets are important to guide the regenerating cells to the area of healing. The PRF is one such material that holds on to these growth factors enmeshed in the fibrin network, resulting in their sustained release over a period of time that can accelerate the wound-healing process.

The results are also in agreement with the study by Shah and Gujjari,¹⁵ who stated that PRF developed in France by Choukroun et al is a second-generation platelet concentrate widely used to accelerate soft and hard tissue

healing. It is a strictly autologous fibrin matrix containing a large quantity of platelet and leukocyte cytokines. It has also been shown to stimulate the growth of osteoblasts and periodontal ligament cells, both of which are significant for the regeneration of periodontal defects.

The results are also in accordance with Goswami et al¹⁶ who stated clinical and radiographic results of an intrabony periodontal defect treated with PRF.

The results are also in accordance with Mathur et al,¹⁷ who compared clinically and radiographically the efficacy of autologous PRF and autogenous bone graft obtained using bone scrapper in the treatment of intrabony periodontal defects and stated that although both gave similar results, using PRF is a safer, cheaper, less technique sensitive, and minimally invasive procedure.

CONCLUSION

The present study was an attempt to comparatively evaluate the regenerative potential of PRF with MTF and PRF alone in the treatment of intrabony periodontal defects.

Results showed an improvement in clinical parameters (plaque index, gingival index, PD, and RAL) as compared with baseline in both the groups. Statistically significant results were obtained in both the groups, with group I exhibiting higher statistically significant values as compared with group II.

Radiographically, there was significant reduction in defect depth and defect volume compared with baseline in both the groups, with group I exhibiting higher statistically significant values as compared with group II for defect depth reduction.

Both the treatment modalities (PRF + MTF and PRF alone) were found to be effective both clinically and radiographically in the treatment of IBDs.

However, the combination of PRF + MTF was proven to be better than PRF alone.

Further, long-term clinical trials with larger samples of various drug concentrations and longer durations should be carried out to assess a complete periodontal regeneration rather than bone regeneration.

ACKNOWLEDGMENT

Authors would like to thank Dr SA Sreenivasan for his valuable opinion and support.

REFERENCES

1. Tatakis DN, Kumar PS. Etiology and pathogenesis of periodontal diseases. *Dent Clin North Am* 2005 Jul;49(3):491-516.
2. Dohan DM, Choukroun J, Diss A, Dohan SL, Dohan AJ, Mouhyi J, Gogly B. Platelet-rich fibrin (PRF): a second-generation platelet concentrate. Part I: Technological concepts and evolution. *Oral Surg Oral Med Oral Pathol Oral Radiol Endod* 2006 Mar;101(3): e37-e44.

3. Dohan Ehrenfest DM, Rasmusson L, Albrektsson T. Classification of platelet concentrates: from pure platelet-rich plasma (P-PRP) to leucocyte- and platelet-rich fibrin (L-PRF). *Trends Biotechnol* 2009 Mar;27(3):158-167.
4. Dohan DM, Choukroun J, Diss A, Dohan SL, Dohan AJ, Mouhyi J, Gogly B. Platelet-rich fibrin (PRF): a second-generation platelet concentrate. Part III: Leucocyte activation: a new feature for platelet concentrates? *Oral Surg Oral Med Oral Pathol Oral Radiol Endod* 2006 Mar;101(3):e51-e55.
5. Dohan DM, Choukroun J, Diss A, Dohan SL, Dohan AJ, Mouhyi J, Gogly B. Platelet-rich fibrin (PRF): a second-generation platelet concentrate. Part II: Platelet-related biologic features. *Oral Surg Oral Med Oral Pathol Oral Radiol Endod* 2006 Mar;101(3):e45-e50.
6. Zhen D, Chen Y, Tang X. Metformin reverses the deleterious effects of high glucose on osteoblast function. *J Diabetes Complications* 2010 Sep-Oct;24(5):334-344.
7. Mohapatra A, Parikh RK, Gohel MC. Formulation, development and evaluation of patient friendly dosage forms of metformin, Part-II: Oral soft gel. *Asian J Pharm* 2008 Jul-Sep;2(3):172-176.
8. Cortizo AM, Sedlinsky C, McCarthy AD, Blanco A, Schurman L. Osteogenic actions of the antidiabetic drug metformin on osteoblasts in culture. *Eur J Pharmacol* 2006 Apr 24;536(1-2):38-46.
9. Pradeep AR, Nagpal K, Karvekar S, Patnaik K, Naik SB, Guruprasad CN. Platelet-rich fibrin with 1% metformin for the treatment of intrabony defects in chronic periodontitis: a randomized controlled clinical trial. *J Periodontol* 2015 Jun;86(6):729-737.
10. Bak EJ, Park HG, Kim M, Kim SW, Kim S, Choi SH, Cha JH, Yoo YJ. The effect of metformin on alveolar bone in ligature-induced periodontitis in rats: a pilot study. *J Periodontol* 2010 Mar;81(3):412-419.
11. Agarwal A. Osteogenic action of antidiabetic drug metformin in periodontal disease. *J Pharm Bioallied Sci* 2013 Oct-Dec;5(4):327.
12. Pradeep AR, Rao NS, Naik SB, Kumari M. Efficacy of varying concentrations of subgingivally delivered metformin in the treatment of chronic periodontitis: a randomized controlled clinical trial. *J Periodontol* 2013 Feb;84(2):212-220.
13. Jeyabalan J, Viollet B, Smitham P, Ellis SA, Zaman G, Bardin C, Goodship A, Roux JP, Pierre M, Chenu C. The antidiabetic drug metformin does not affect bone mass in vivo or fracture healing. *Osteoporos Int* 2013 Oct;24(10):2659-2670.
14. Khiste SV, Tari RN. Platelet-rich fibrin as a biofuel for tissue regeneration. *ISRN Biomaterials* 2013;2013:1-6.
15. Shah MP, Gujjari SK. Alveolar ridge augmentation utilizing platelet rich fibrin in combination with mineralised freeze-dried bone allograft – a case report. *Int J Basic App Med Sci* 2013 Jan-Apr;3(1):18-23.
16. Goswami Y, Mishra R, Agrawal AP, Lavanya AA. Treatment of an intraosseous defect with platelet-rich fibrin (PRF) – a case report. *IOSR J Dent Med Sci (IOSR-JDMS)* 2015 Feb;14(2): 93-96.
17. Mathur A, Bains VK, Gupta V, Jhingran R, Singh GP. Evaluation of intrabony defects treated with platelet rich fibrin or autogenous bone graft: a comparative analysis. *Eur J Dent* 2015 Jan-Mar;9(1):100-108.