

CASE REPORT

Novel Decision-making to extract or save the Tooth in a Smart Way

¹Priyanka H Sawant, ²N Vimala, ³Bhawana Pawar, ⁴Leena Padhye

ABSTRACT

The term endodontic-periodontal lesions have been used to describe lesions due to inflammatory products found in varying degrees in both pulp and periodontal tissues. These tissues share common embryonic derivation, vasculatures, lymphatic, neural pathways and microflora. As the tooth matures and the root is formed, three main avenues are created between pulp and periodontal ligament, i.e. dentinal tubules, lateral and accessory canals, and apical foramen. Radiographic and clinical evaluation can help clarify the nature of the problem. Root canal treatment was done followed by periodontal therapy with the use of platelet-rich fibrin (PRF) as the regenerative material of choice. PRF has been a breakthrough in the stimulation and acceleration of tissue healing. The success of both periodontal and endodontic therapy depends on the elimination of both disease processes, whether they exist separately or as a combined lesion. A clinical case is presented in which a periodontal endodontic lesion has been successfully treated with a combination of conventional endodontic therapy and regenerative periodontal surgery followed by restoration of esthetics with fixed prosthesis.

Keywords: Endo-perio lesion, Microflora, Platelet-rich fibrin.

How to cite this article: Sawant PH, Vimala N, Pawar B, Padhye L. Novel Decision-making to extract or save the Tooth in a Smart Way. *Int J Oral Care Res* 2017;5(1):78-81.

Source of support: Nil

Conflict of interest: None

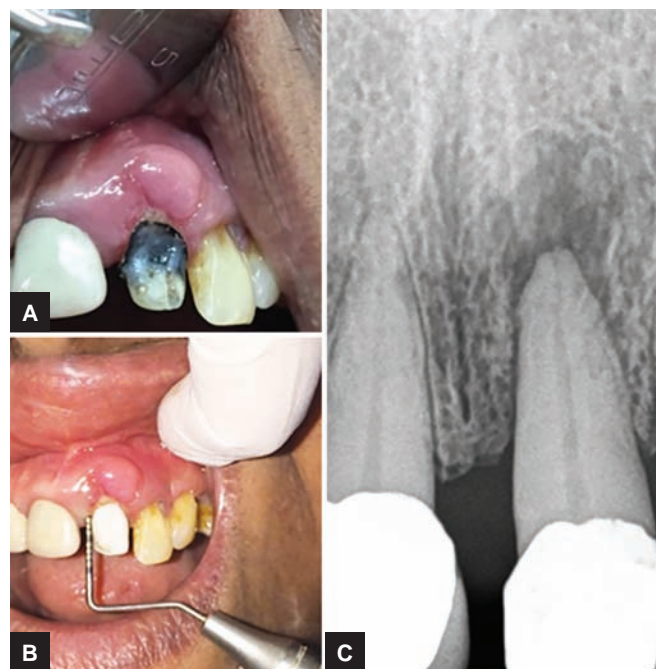
INTRODUCTION

Periodontium and dental pulp are connected by their proximity to the presence of apical and lateral radicular foramina, which route the pathogens between these two distinct anatomical areas. Pulp-periodontal interrelations have varied communicating pathways that one can conclude them to be a "single continuous system".¹ Associated disease with these structures, described by Simring and Goldberg,² was termed as "endo-perio lesion." Treatment

primarily depends on the cause of pulp disease and extent of periodontal defect, and one encounters a great challenge as far diagnosis and prognosis are concerned.³

CASE REPORT

A 75-year-old female patient reported to the dental hospital with chief complaint of swelling and pain in the upper left front tooth. History revealed a swelling in relation to 21 with intermittent pain, which started spontaneously and subsided on taking analgesics. Patient was under medication for diabetes and hypertension. On intraoral examination, fixed prosthesis in 11, 12, 13, and 21 was seen and on removal of 21 porcelain-fused-to-metal (PFM) crown, discoloration and periodontal abscess in the gingiva were seen (Fig. 1A). Periodontal examination revealed probing depth (Fig. 1B) of 6 mm on the labial, 8 mm on mesial, and 5 mm on distal with grade II mobility; tooth was tender on percussion and negative response on electric pulp testing confirmed it as nonvital. Radiographic examination (Fig. 1C) revealed periapical radiolucency with loss of lamina dura. According to Simon et al, a diagnosis of a primary periodontal disease with secondary endodontic lesion was done for 21.



Figs 1A to C: (A) Preoperative clinical abscess with 21; (B) pocket depth 1; and (C) preoperative radiograph of periapical lesion

^{1,3}Senior Resident, ²Professor, ⁴Professor and Head

^{1,2,4}Department of Conservative Dentistry and Endodontics, DY Patil School of Dentistry, Navi Mumbai, Maharashtra, India

³Department of Periodontics and Implantology, DY Patil School of Dentistry, Navi Mumbai, Maharashtra, India

Corresponding Author: Priyanka H Sawant, Senior Resident, Department of Conservative Dentistry and Endodontics, DY Patil School of Dentistry, Navi Mumbai, Maharashtra, India, e-mail: priyanka.sawant1989@yahoo.com

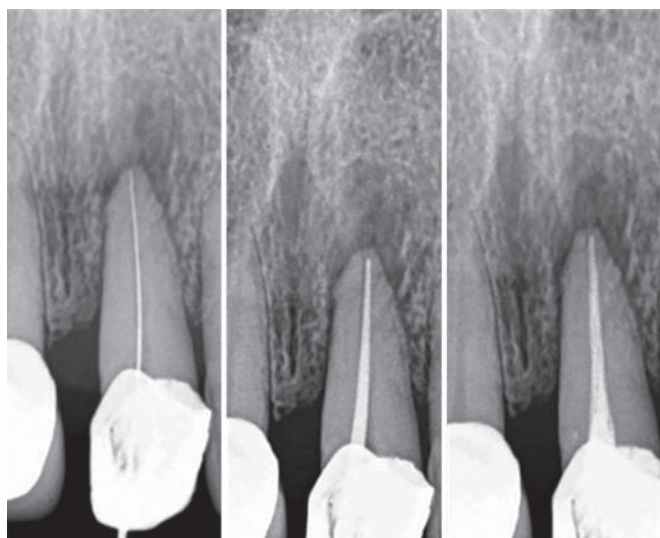


Fig. 2: Endodontic therapy

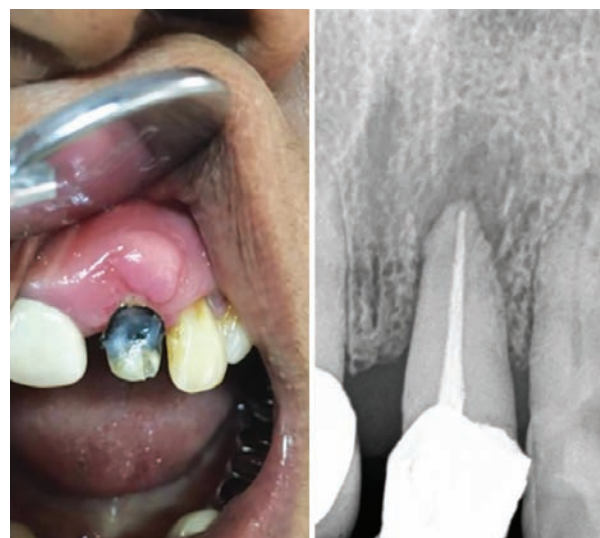

Fig. 3: Postendodontic therapy recall

Root canal treatment (Fig. 2) was performed first for the 21. Patient was reviewed (Fig. 3) for 2 weeks after endodontic therapy. It was evident that the endodontic treatment succeeded in providing a symptom-free state, but the healing was not satisfactory. Based on the clinical and radiographic features, conventional periodontal therapy was instituted with scaling and root planing followed by periodontal flap surgery.

The tooth was splinted prior to surgery with composite resin for the stability and support, which aid in decreased mobility. Sulcular incision was given to elevate a full-thickness flap from mesial of 21 to mesial of 23. After raising the flap, complete debridement was done, which revealed loss of alveolar bone on facial aspect, indicating dehiscence and osseous defect up to the apex of the tooth number 21. Thorough root planing and curettage were performed, and the site was filled with platelet-rich fibrin membrane as regenerative material. Flap was repositioned and interrupted suturing was done with silk suture material (Figs 4A to C).

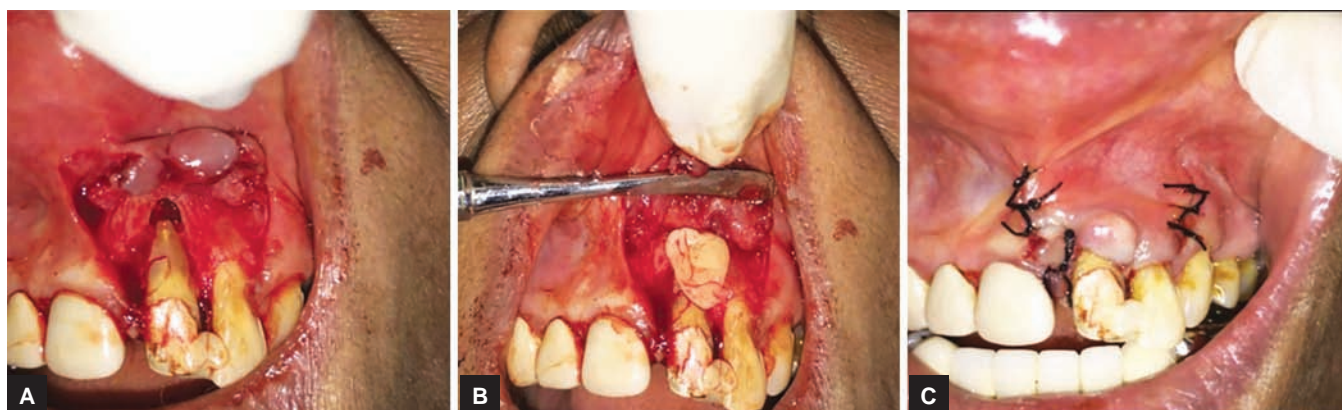
Patient was given postoperative instruction, and analgesic for 3 days (ibuprofen 400 mg) was prescribed.

Patient was recalled after a week for suture removal; the soft tissue healing was uneventful with slight reduction in swelling (Figs 5A and B).

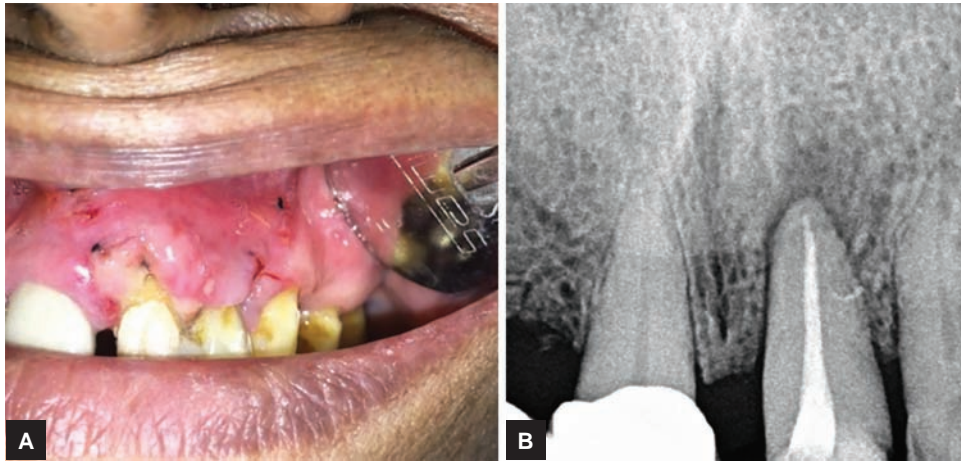
The patient was put on regular review of 3 months, which showed remarkable bone healing with probing depth to normalcy and no mobility. As per patient's demand for esthetic, fixed prosthesis of PFM, ceramic crown was given. At 1-year recall, patient showed satisfactory clinical outcome of the combined therapy with successful healing on radiograph (Figs 6 and 7A to C).

DISCUSSION

Endo-perio lesions can have varied pathogenesis, which ranges from quite simple to a relatively complex one.⁴ Cases with greater probing depths, present along more than one surface of a tooth, are unlikely the lesion of endodontic origin. In majority of such cases, the lesion is primarily periodontal in origin. In such cases, endodontic treatment fails to resolve the problem completely and requires both endodontic and periodontal regenerative procedures.⁵



Figs 4A to C: Periodontal flap surgery (flap reflection, PRF placement, suturing)



Figs 5A and B: Suture removal

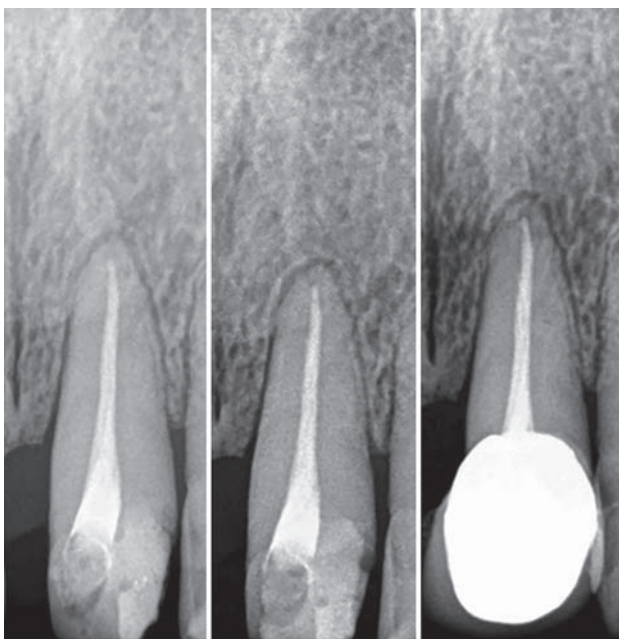
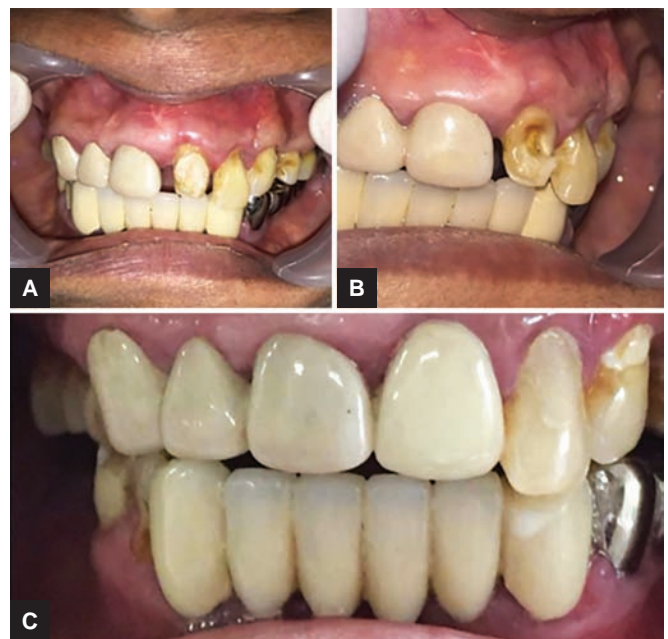

Fig. 6: Radiographic recall



Figs 7A to C: Clinical recall

In the above-mentioned case, patient had chief complaint of swelling with mobility and deep pocket, confirming it to be primary periodontal lesion with a secondary endodontic involvement.

The cleaning and shaping of the root canals was performed and additional interappointment calcium hydroxide was placed to render the root canal system free of cultivable bacteria. Calcium hydroxide has bactericidal, anti-inflammatory action, which favors repair. It also inhibits periodontal contamination from instrumented canals via patent channels connecting the pulp and periodontium before periodontal treatment removes the contaminants.⁴

In the present case, endodontic therapy was performed first followed by periodontal therapy after 2 weeks. This sequence of treatment allows sufficient time for initial tissue healing and better assessment of

the periodontal condition. It also reduces the potential risk of infection with bacteria and their by-products in the initial healing phase.

El-Sharkawy et al⁶ studied the regenerative potential of platelet-rich fibrin (PRF), and suggested that the administration of growth factors may be combined with tissue regeneration techniques in the repair of intrabony defects, furcations, and cyst cavities.

The PRF was first developed by Choukroun et al in France in 2001. It belongs to the new generation of platelet concentrates, which is in the form of a platelet gel. It is made from autologous blood and is used to deliver growth factors in high concentrations to the site of a bone defect, offering several advantages including promoting wound healing, bone growth, maturation, graft stabilization, wound sealing, and hemostasis. The PRF is used as both a graft material and a membrane. To improve the

outcome of these treatments, clinicians and scientists are investigating the use of PRF in dentistry as a way to enhance the body's natural wound-healing mechanisms.⁷

Thorough proper endodontic treatment is a key factor for treatment success; the prognosis of combined lesions depends upon the efficacy of periodontal therapy too. Patient also gave a medical history of diabetes and hypertension, which added up for the slow healing, but the host response also plays a significant role, which was observed in this case. Case was reviewed with reduction in the probing depth, tooth mobility, and satisfactory bony healing. It is also possible to restore esthetics in such a compromised situation with the use of full veneer metal ceramic crown.

CONCLUSION

The opinion is that the true combined lesions are a diagnostic dilemma, and it is usually very difficult to diagnose the actual cause. Treatment plan is always biphasic, wherein "complete debridement and disinfection of the root canal system" is performed, followed by a period

of observation and then the institution of "periodontal therapy." In this case report, successful outcome of the treatment plan was achieved.

REFERENCES

1. Foce, E. Endo-periodontal lesions. London: Quintessence Publishing; 2011;3-5.
2. Simring M, Goldberg M. The pulpal pocket approach: retrograde periodontitis. *J Periodontol* 1964 Jan-Feb;35(1):22-48.
3. Rotstein I, Simon JH. The endo-perio lesion: a critical appraisal of the disease condition. *Endodontic Topics* 2006 Mar;13(1): 34-56.
4. Singh P. Endo-perio dilemma: a brief review. *Dent Res J* 2011 Winter;8(1):39-47.
5. Sultan N. Endo-periodontal lesion presenting a diagnostic dilemma: a case report. *Int J Res Dent* 2013 May-Jun;3(3):24-31.
6. El-Sharkawy H, Kantarci A, Deady J, Hasturk H, Liu H, Alshahat M, Van Dyke TE. Platelet rich plasma: growth factors and pro- and anti-inflammatory properties. *J Periodontol* 2007 Apr;78(4):661-669.
7. Corso MD, Toffler M, Ehrenfest DM. Use of an autologous leukocyte and platelet-rich fibrin (L-PRF) membrane in post-avulsion sites: an overview of Choukroun's PRF. *J Implant Adv Clin Dent* 2010 Jan;9:27-35.