

A Comparative Study of Three Different Methods for evaluating Width of Alveolar Ridge prior to Implant Placement: An *in vivo* Study

¹Bhagyashree H Dave, ²Shreyansh Sutaria, ³Shruti Mehta, ⁴Priya Shah, ⁵Trishla Prajapati, ⁶Mohil Asnani

ABSTRACT

Introduction: During treatment planning for dental implant placement, there is a need for assessment of alveolar bone. Bone evaluation limited to the use of panoramic and/or peri-apical radiographs may be insufficient, as it provides only two-dimensional information about the implant sites. So, three-dimensional information of implant site, such as computed tomography (CT) and ridge mapping technique should be evaluated for better implant placement.

Aims and objectives: The aim of the study is to compare the techniques, i.e., ridge mapping, direct surgical exposure, and CT scan, which are used to measure the alveolar ridge bone width and determine their accuracy in the clinical application.

Clinical significance: A comparative study of three different methods to identify simplified and accurate method to evaluate width of the alveolar ridge prior to implant placement.

Materials and methods: The study will be conducted on patients who needed replacement of edentulous span with dental implant. Width of alveolar ridge will be studied by above-mentioned three techniques at two points (3 mm from the crest of ridge and 6 mm from the crest of ridge) with measurements at site of surgical exposure as control. The measurements obtained from these three different techniques will be evaluated by statistical analysis.

Keywords: Alveolar ridge, Computed tomography, Implant placement.

How to cite this article: Dave BH, Sutaria S, Mehta S, Shah P, Prajapati T, Asnani M. A Comparative Study of Three Different Methods for evaluating Width of Alveolar Ridge prior to Implant Placement: An *in vivo* Study. Int J Oral Care Res 2017;5(1):53-60.

¹Postgraduate Student (3rd Year), ^{2,6}Private Practitioner
³Professor and Head, ⁴Postgraduate Student (2nd Year)
⁵Postgraduate Student (1st Year)

^{1,3-5}Department of Prosthodontics and Crown and Bridge
College of Dental Sciences & Research Center, Ahmedabad
Gujarat, India

²Department of Oral Medicine and Radiology, Aarsh Dental
Clinic, Ahmedabad, Gujarat, India

⁶Department of Conservative Dentistry and Endodontics, Aarsh
Dental Clinic, Ahmedabad, Gujarat, India

Corresponding Author: Bhagyashree H Dave, Postgraduate
Student (3rd Year), Department of Prosthodontics and Crown
and Bridge, College of Dental Sciences & Research Center
Ahmedabad, Gujarat, India, Phone: +917016123494, e-mail:
mohil29@gmail.com

Source of support: Nil

Conflict of interest: None

INTRODUCTION

Dental implant therapy has been used increasingly frequently for the rehabilitation of missing dentition, replacing conventional therapies in the areas of complete and partial edentulism, and single tooth anodontia.¹⁻⁵ The use of dental implants to support prosthodontic restorations has a high success rate.⁶ To achieve long-term success of dental implants, evaluation of the dimensions of the resorbing alveolar process must be accurate, because an implant should be surrounded by at least 1 mm of bone.⁷ Careful diagnosis and treatment planning are critical for a favorable outcome.

Commonly used radiographic techniques, such as intraoral periapical and panoramic views are hampered by image distortion and inability to image in a buccolingual cross section, as they produce two-dimensional (2D) image giving information about length of bone, visualization of nerves and vessels, but do not provide information regarding width of bone about implant sites.⁸ The buccolingual ridge width can be evaluated by computed tomography (CT), ridge mapping, trans-tomography, ultrasonography, and direct Caliper measurements following surgical exposure of the bone.⁸⁻¹⁴

Tomography and CT provide information of the quantity and quality of bone and critical anatomic structures.^{15,16}

In ridge mapping using a caliper device under local anesthesia, the pointed tips of the instrument penetrate buccal and lingual soft tissue layers and measure the buccolingual width of the underlying bone. This procedure is performed chair-side and provides instant information. To determine this, ridge mapping needs to be compared to what would seem to be the most accurate measurement, i.e., direct caliper measurements following surgical exposure of the bone.^{8,13}

The direct caliper measurement following surgical exposure of alveolar bone of the ridge gives the most accurate measurement.^{8,13}

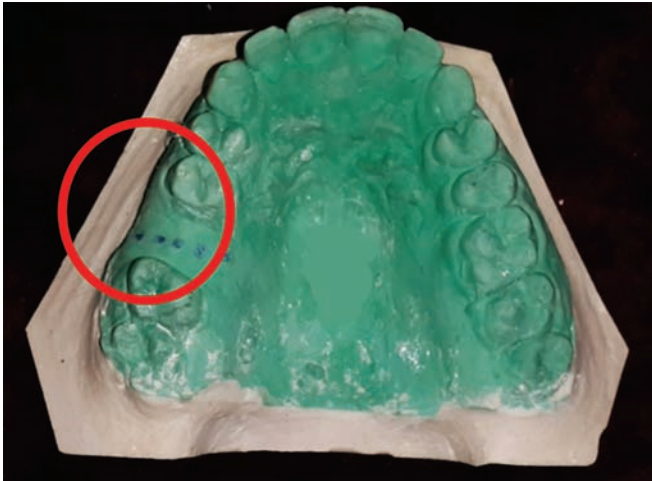

Fig. 1: Study model marked with reference points

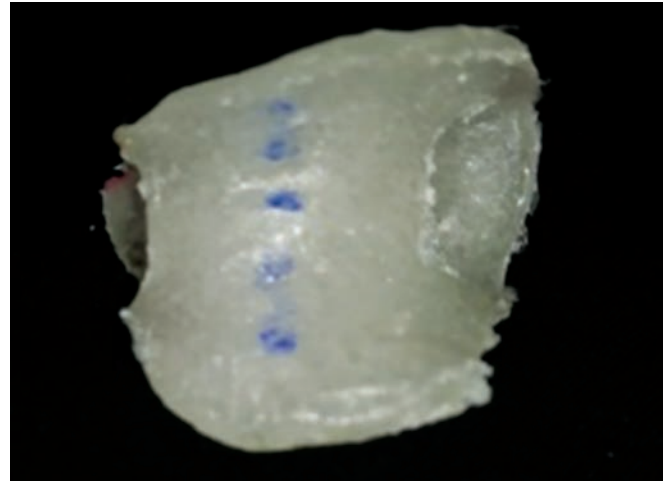


Fig. 2: Stent made up of clear acrylic with reference points

MATERIALS AND METHODS

Subjects

Eighteen patients with 33 implant sites were selected from the OPD of Prosthodontics and Crown and Bridge department, College of Dental Sciences & Research Center, Ahmedabad, Gujarat, India. Out of these, 30 cases were selected for the study and 3 cases were excluded during treatment planning procedure (2 after ridge mapping procedure and 1 after CT scan procedure). After explanation of the proposed study criteria, including alternate treatment, potential risks and benefits, the participants were asked to sign a consent form prior to the implant surgery. Approval from ethical committee of the institute was taken.

Nonpregnant, healthy subjects with partially edentulous ridge having at least one periodontally healthy and stable abutment for radiographic stent, and at least 3 months of healing period after tooth extraction with good oral hygiene were included for study. Subjects having smoking habits and debilitating diseases were excluded.

Methods

Study was divided into three groups based on the method of measurements of alveolar ridge width dimensions.

1. *Group I:* Alveolar ridge dimensions assessed by cone beam computed tomography (CBCT)
2. *Group II:* Ridge mapping measurements before surgical flap reflection
3. *Group III:* Direct caliper measurements following surgical exposure of the bone

Fabrication of Stent for Measurements

A study model was obtained from an alginate impression. On the study model (with edentulous span),

first point was marked on the crest of ridge (reference point) in reference to the adjacent teeth. Then one point (point 1) was marked at 3 mm distance from the reference point and another point (point 2) was marked at 6 mm distance from the reference point. Points 1 and 2 were marked on both buccal and lingual/palatal aspect (Fig. 1).

A clear acrylic resin stent was fabricated over the study model with reference points (Fig. 2). The reference points were visible over the stent through the transparent acrylic resin material: A 1 mm diameter hole was then made over these 5 points (Fig. 3).

In this manner, the stent provided consistent buccal and lingual locations for the assessment of ridge width. The holes in the guidance stent were filled with gutta-percha (Fig. 4). Due to the radiopaque property of gutta-percha material, the acrylic stent was converted into radiographic stent. And this stent was used during the preoperative tomography to provide radiopaque landmarks indicating the locations for comparative radiographic ridge width measurements.

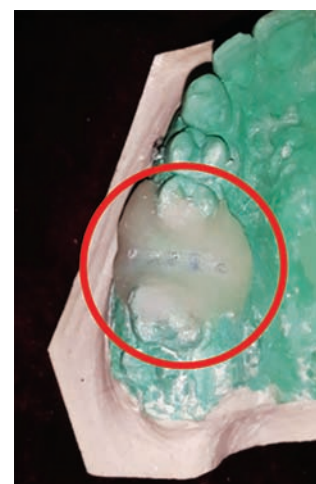

Fig. 3: Drilled reference points with 1 mm diameter




Fig. 4: Holes filled with gutta-percha

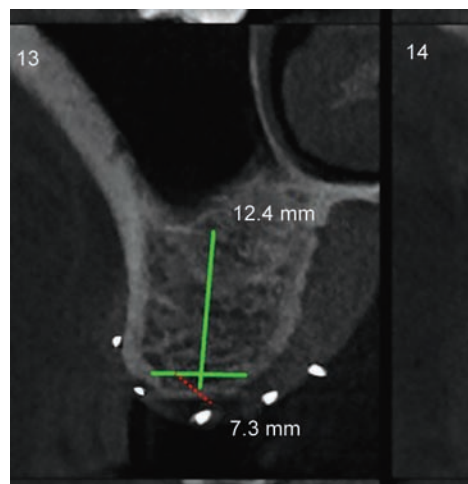
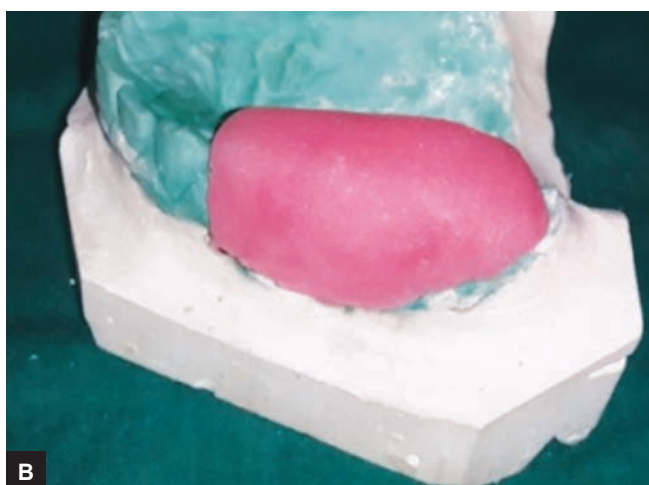
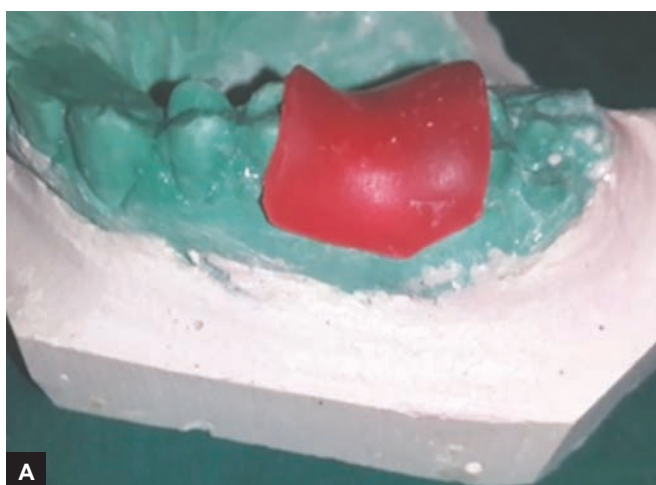

Fig. 5: Cross-sectional slice having all five reference points



Figs 6A and B: Self-cure acrylic resin custom tray with wax spacer

Group I: Alveolar Ridge Dimensions assessed by CBCT

The stent with gutta-percha in the guide holes after disinfection with nanzidone povidone-iodine solution IP microbial solution (5%) was placed in the patient's mouth before the images are obtained. The CBCT was performed with subjects in a supine position. The device was operated at 110 kV with an exposure time ranging from 5.4 to 9.0 seconds depending on the size of the area to be analyzed (maxilla, mandible, or both). An image for measurement that showed the clearest gutta-percha imprints for the buccal and lingual aspects at all levels of measurements (3 and 6 mm) was selected (Fig. 5). The largest distance between the buccal and lingual bone walls was recorded to the nearest 0.1 mm using the software's built-in measurement tool.

Group II: Ridge Mapping Measurements before Surgical Flap Reflection

On the study model, a self-cure acrylic resin custom tray was fabricated with wax spacer (Fig. 6). After removal

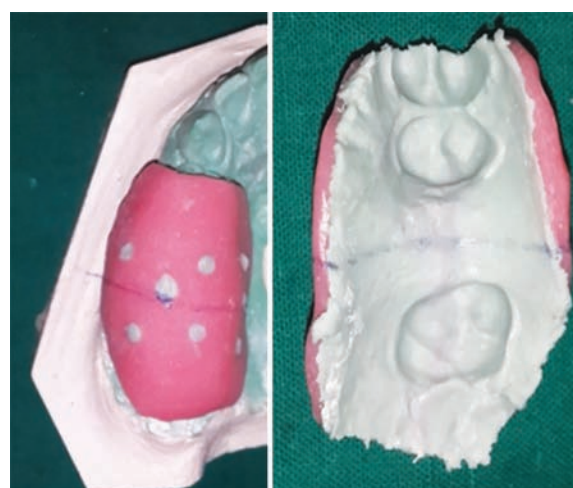

Fig. 7: Vinyl polysiloxane impression

of the wax spacer, impression was made using vinyl polysiloxane impression material (Fig. 7).

A line was drawn on the study model taking these points as reference and further extended on buccal and lingual/palatal aspect to serve as a reference for the sectioning of ridge mapping stent (Fig. 8). The reference line

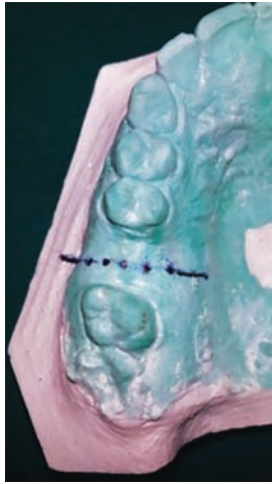


Fig. 8: Reference line passing through all 5 points

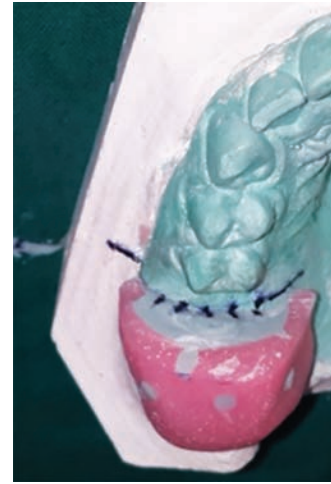


Fig. 9: Transfer of reference points from cast onto the ridge mapping stent

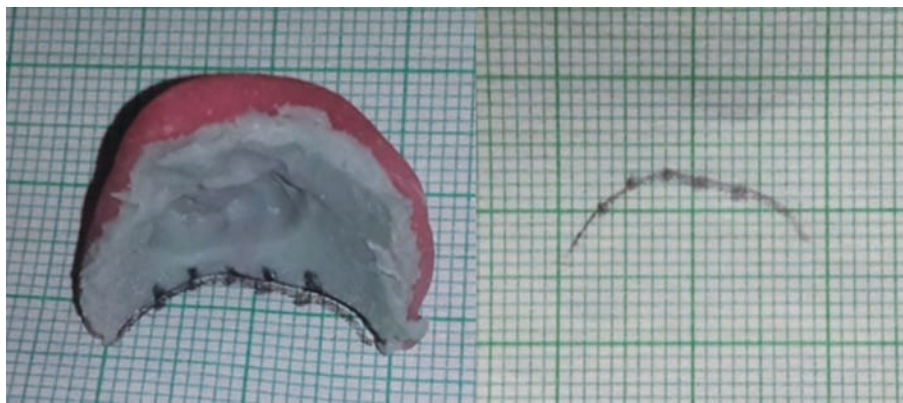


Fig. 10: Points transferred on graph paper

was marked with marker over special tray to cut along that line using saw and the points were transferred to the impression for ridge mapping (Fig. 9).

The cut half of the impression with the markings was then traced on a graph paper to give the shape of the ridge. The points on the impression were transferred on the graph paper (Fig. 10).

The same impression after disinfecting was then transferred to the patient's mouth and the thickness of mucosa (under local anesthesia) on points 1 and 2 on both buccal and lingual/palatal aspect were measured with William's periodontal probe (Fig. 11) and transferred on the graph paper having ridge tracing (Fig. 12).

Now, the exact contour of the alveolar bone was obtained after probing and the width of ridge was measured from two points on buccal side to the two points on lingual side (Fig. 13).

Group III: Direct Caliper Measurements following Surgical Exposure of the Bone

Following surgical flap reflection, ridge width was measured directly on the exposed bone at the various locations of the guide holes using the ridge mapping caliper device and stent as described previously (Figs 14A to C).

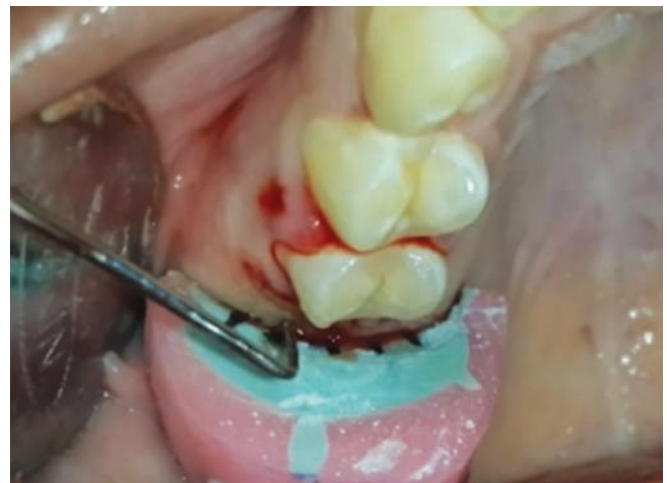

Fig.11: Thickness of mucosa was measured at points 1 and 2 on both buccal and lingual side with William's periodontal probe

We have taken null hypothesis as there was no significant difference between three groups in the study.

RESULTS

According to the results obtained from the above study, Table 1 shows that mean alveolar ridge dimensions obtained from three methods, i.e., CBCT (group I), Ridge




Fig. 12: Mucosal thickness was transferred to graph paper having ridge tracing

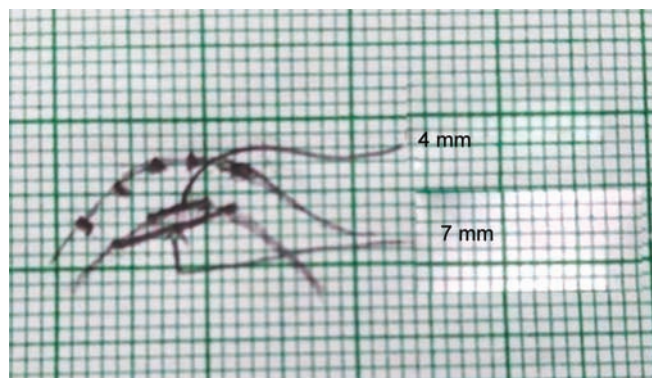
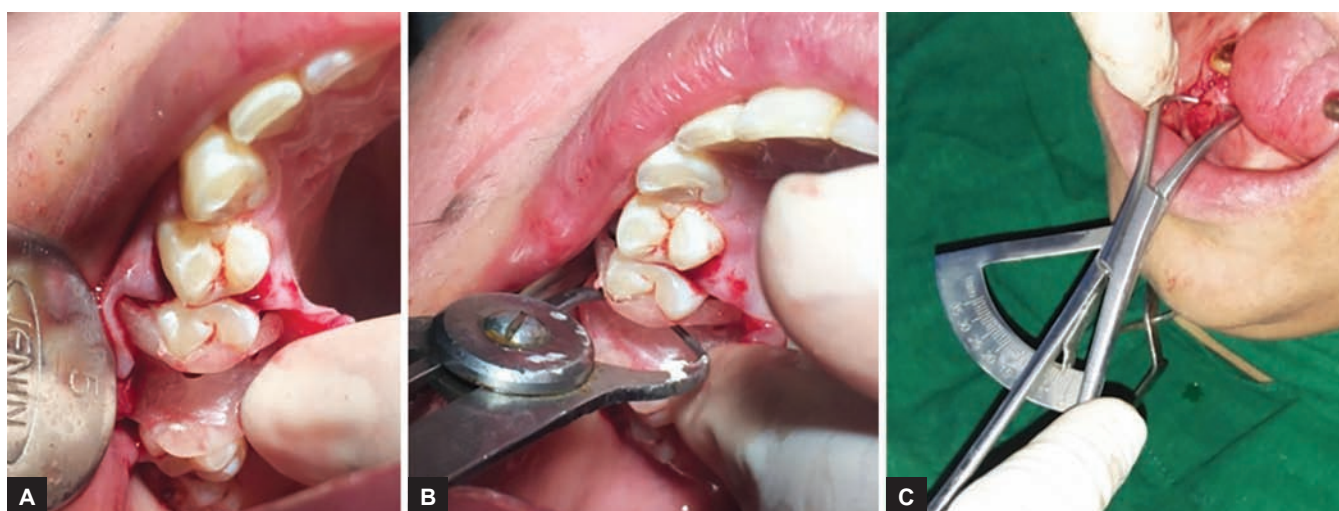


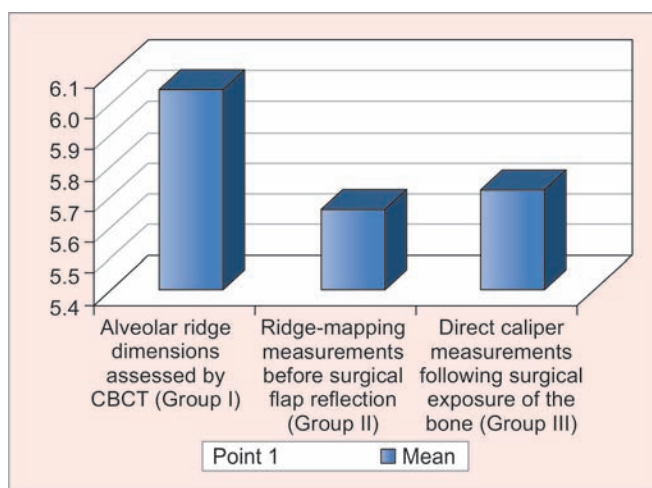
Fig. 13: Measured width of ridge from two points on buccal side to the two points on lingual side



Figs 14A to C: Measurements made using caliper with stent in place after surgical exposure of bone

Table 1: Mean and standard deviation of all three groups

Groups	Point of measurements	n	Mean	Standard deviation
Alveolar ridge dimensions assessed by CBCT (group I)	Point 1	30	6.05	1.947
	Point 2	30	8.1	1.7582
Ridge-mapping measurements before surgical flap reflection (group II)	Point 1	30	5.663	2.1037
	Point 2	30	8.012	1.875
Direct caliper measurements following surgical exposure of the bone (group III)	Point 1	30	5.725	1.9797
	Point 2	30	7.738	1.7952

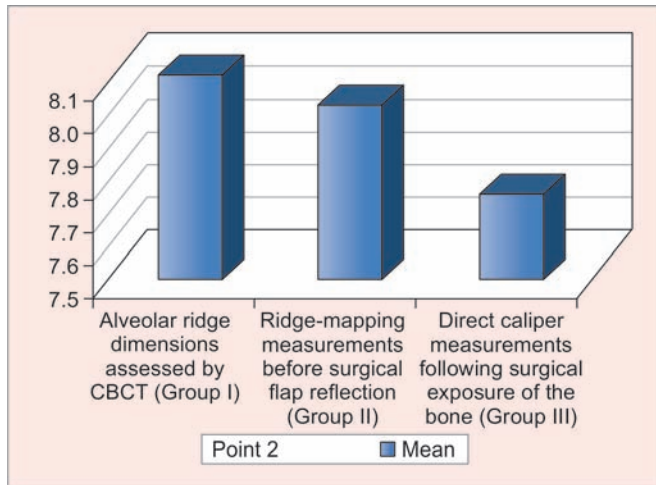


Graph 1: Mean value of all three groups at point 1

mapping (group II), and direct caliper measurements following surgical exposure of the bone (group III) was 6.050 mm, 5.663 mm, and 5.725 mm respectively for point 1 and 8.100 mm, 8.012 mm, and 7.738 mm respectively for point 2. The graph depiction of table is shown in Graphs 1 and 2.

Tables 2 and 3 show mean difference of the recorded alveolar ridge width in CBCT (group I) and ridge

mapping procedure (group II) compared to direct caliper measurements following surgical exposure of the bone (group III) at points 1 and 2 respectively. The mean difference of alveolar ridge width for CBCT (group I) was 0.325 mm and 0.063 mm for ridge mapping procedure at point 1 and 0.362 mm for direct surgical exposure and



Graph 2: Mean value of all three groups at point 2

0.275 mm for ridge mapping procedure at point 2. The graph depiction of table is shown in Graphs 3A and B.

The p value for groups I to III was found to be non-significant ($p > 0.05$ is highly statistically significant). Thus, in this study, the alveolar ridge dimensions measured by CBCT, ridge mapping procedure and direct surgical exposure were same at points 1 and 2. There was no significant difference ($p > 0.05$) between the mean values of three groups and hence, null hypothesis accepted.

Table 2: Comparison with direct caliper measurements following surgical exposure of the bone (group III) at point 1

	Mean difference	Significance
Alveolar ridge dimensions assessed by CBCT (group I) at point 1	0.325	1.00 NS
Ridge mapping measurements before surgical flap reflection (group II) at point 1	0.063	1.00 NS

NS: Non significant

DISCUSSION

In all phases of clinical dentistry, careful planning and diagnosis result in a more predictable outcome. Fabrication of an implant-supported tooth restoration, both esthetically and functionally, depends on the ridge morphology and the orientation of implant. The contour of the residual bone must be evaluated prior to implant placement to assure proper implant positioning.

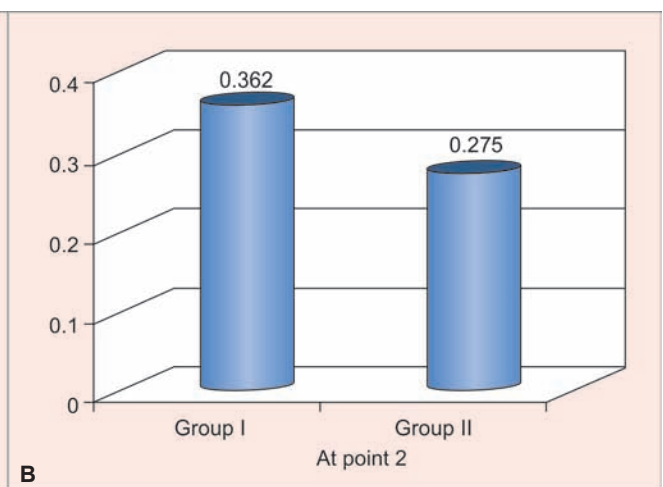
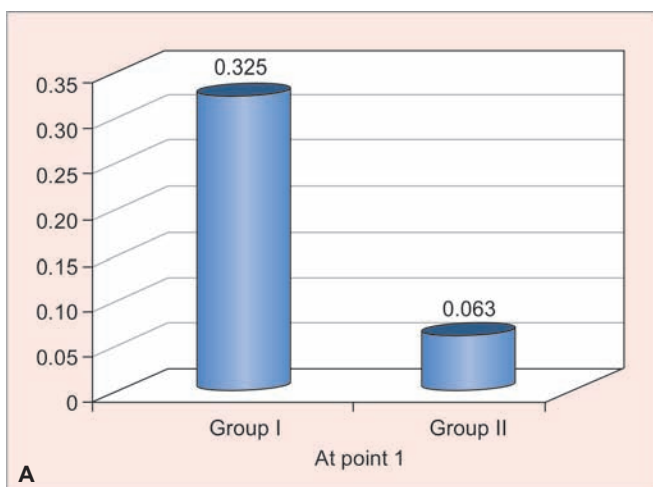
Preoperative radiographic assessment has assumed an increasingly important role in treatment planning for implant-supported prostheses.¹⁷ Bone quantity and quality will influence the choice of implants with respect to their number, diameter, length, and type. A panoramic radiograph gives an overall view and periapical radiographs of the edentulous region show the bone height, mesiodistal space, as they are 2D radiographs.^{18,19} Nevertheless, these diagnostic methods reveal no information on the sagittal bony morphology (width of ridge) and on the ideal orientation to give the implant to meet restorative requirements.

And hence, for three-dimensional visualization of bone morphology, we need to have CBCT of the patient of that region where we want to place the implant.^{15,16} The advantages of CBCT-based systems are uniform magnification, a high-contrast image with a well-defined image layer free of blurring. The disadvantages of CBCT

Table 3: Comparison with direct caliper measurements following surgical exposure of the bone (group III) at point 2

	Mean difference	Significance
Alveolar ridge dimensions assessed by CBCT (group I) at point 2	0.362	1.00 NS
Ridge-mapping measurements before surgical flap reflection (group II) at point 2	0.275	1.00 NS

NS: Non significant



Graphs 3A and B: Comparison with direct caliper measurements following surgical exposure of the bone (group III)

include limited availability of reconstructive software, expense, higher doses of radiation compared with conventional tomography, cost, and lack of understanding of the dentist's imaging needs by the radiologic technologists and medical radiologists who acquire and interpret the CT images.

According to the results obtained from this study, there is no significant difference in CBCT and direct surgical exposure measurements of ridges which is similar to the study done by Chen Lc et al.²⁰

The CBCT method for the evaluation of alveolar ridge width measurements is indicated in areas where the ridges are resorbed, maxillary anterior ridge concavities, high lingual frenum areas, and vestibular depth is less where ridge mapping is not feasible.

The ridge width can also be evaluated by ridge mapping calipers technique. This technique involves penetration of the buccal and lingual mucosa down to bone (following the administration of local anesthetic) with calipers designed for this purpose. A series of measurements of the proposed implant site can be made prior to reflection of a mucoperiosteal flap. This technique has been advocated by Wilson and Traxler et al, who suggest that it is a convenient and reliable method for assessing suitability of potential implant sites.^{11,12} The ridge mapping method has the advantage of being simple to use, and avoids exposure to radiation for the patient.

According to the results obtained from the study, there is no significant difference in direct surgical exposure and ridge mapping measurements, which supports the use of ridge mapping procedure for the evaluation of alveolar ridge width for partially edentulous ridges which is similar to the study done by Perez et al and Goulet et al.^{21,22}

In cases where the pattern of resorption appears more regular, and where mucosa is of a more even thickness, ridge mapping with panoramic and intraoral radiography may prove adequate

CONCLUSION

Within the limitations of the study, the following conclusions were drawn:

- There is no significant difference in the measurements obtained by direct surgical exposure technique and ridge mapping technique
- There is no significant difference in the measurements obtained by CBCT technique and direct surgical exposure technique
- Thus, the measurements of alveolar ridge width dimensions obtained by all the three techniques, i.e., Ridge mapping, CBCT scan, and direct surgical exposure are found to be the same at points 1 and 2.

Since the sample size was relatively small, further studies are recommended with data of larger size.

REFERENCES

1. Adell R, Lekholm U, Rockler B, Brånemark PI. A 15-year study of osseointegrated implants in the treatment of the edentulous jaw. *Int J Oral Surg* 1981 Dec;10(6):387-416.
2. Brånemark PI, Hansson BO, Adell R, Breine U, Lindström J, Hallén O, Ohman A. Osseointegrated implants in the treatment of the edentulous jaw. Experience from a 10- year period. *Scand J Plast Reconstr Surg Suppl* 1977;16:1-132.
3. van Steenberghe D. A retrospective multicentre evaluation of the survival rate of osseointegrated fixtures supporting fixed partial prostheses in the treatment of partial edentulism. *J Prosthet Dent* 1989 Feb;61(2):217-223.
4. Palmer RM, Palmer PJ, Smith BJ. A 5-year prospective study of astra single tooth implants. *Clin Oral Implants Res* 2000 Apr;11(2):179-182.
5. Andersen E, Haanaes HR, Knutsen BM. Immediate loading of single-tooth ITI implants in the anterior maxilla: a prospective 5-year pilot study. *Clin Oral Implants Res* 2002 Jun;13(3): 281-287.
6. Berglundh T, Persson L, Klinge B. A systematic review of the incidence of biological and technical complications in implant dentistry reported in prospective longitudinal studies of at least 5 years. *J Clin Periodontol* 2002; 29(Suppl 3):197-212.
7. Chowdhary R, Chandraker N. Simple diagnostic method to assess the available bone for immediate implant placement in an extracted socket. *J Oral Implantol* 2011 Aug;37(4):473-476.
8. Allen F, Smith DG. An assessment of the accuracy of ridge-mapping in planning implant therapy for the anterior maxilla. *Clin Oral Implants Res* 2000 Feb;11(1):34-38.
9. Williams MY, Mealey BL, Hallmon WW. The role of computerized tomography in dental implantology. *Int J Oral Maxillofac Implants* 1992;7(3):373-380.
10. Ziegler CM, Woertche R, Brief J, Hassfeld S. Clinical indications for digital volume tomography in oral and maxillofacial surgery. *Dentomaxillofac Radiol* 2002 Mar; 31(2):126-130.
11. Wilson DJ. Ridge mapping for determination of alveolar ridge width. *Int J Oral Maxillofac Implants* 1989 Spring;4(1):41-43.
12. Traxler M, Ulm C, Solar P, Lill W. Sonographic measurement versus mapping for determination of residual ridge width. *J Prosthet Dent* 1992 Mar;67(3):358-361.
13. Ten Bruggenkate CM, de Rijcke TB, Kraaijenhagen HA, Oosterbeek HS. Ridge mapping. *Implant Dent* 1994;3(3): 179-182.
14. Bousquet F, Bousquet P, Vazquez L. Transtomography for implant placement guidance in non-invasive surgical procedures *Dentomaxillofac Radiol* 2007 May;36:229-233.
15. Kassebaum DK, Nummikoski PV, Triplett RG, Langlais RP. Cross-sectional radiography for implant site assessment. *Oral Surg Oral Med Oral Pathol* 1990 Nov; 70(5):674-678.
16. Schwarz MS, Rothman SL, Rhodes ML, Chafetz N. Computed tomography: Part II. Preoperative assessment of the maxilla for endosseous implant surgery. *Int J Oral Maxillofac Implants* 1987;2(3):143-148.
17. Frederiksen NL. Diagnostic imaging in dental Implantology. *Oral Surg Oral Med Oral Pathol Oral Radiol Endod* 1995 Nov;80(5):540-554.
18. Lindh C, Petersson A. Radiologic examination for location of the mandibular canal: A comparison between panoramic

- radiography and conventional tomography. *Int J Oral Maxillofac Implants* 1989 Fall;4(3):249-253
19. Ludlow JB, Nason RH Jr, Hutchens LH Jr, Moriarty J. Radiographic evaluation of alveolar crest obscured by dental implants. *Implant Dent* 1995;4(1):13-18.
 20. Chen Lc, Lundgren T, Hallstrom H, Cherel F. Comparison of different methods of assessing alveolar ridge dimensions prior to dental implant placement. *J Periodontol* 2008 Mar;79(3):401-405.
 21. Perez LA, Brooks SL, Wang HL, Eber RM. Comparison of linear tomography and direct ridge mapping for the determination of edentulous ridge dimensions in human cadavers. *Oral Surg Oral Med Oral Pathol Oral Radiol Endod* 2005 Jun;99(6):748-754.
 22. Veyre-Goulet S, Fortin T, Thierry A. Accuracy of linear measurement provided by cone beam computed tomography to assess bone quantity in the posterior maxilla: a human cadaver study. *Clin Implant Dent Relat Res* 2008 Dec;10(4):226-30.