

## ORIGINAL RESEARCH

# Gender Differentiation using Maxillary Sinus

<sup>1</sup>Kunigal S Praveen, <sup>2</sup>Charan Gowda, <sup>3</sup>Ganganna Kokila, <sup>4</sup>S Jayadev, <sup>5</sup>Kumaraswamy Shubha, <sup>6</sup>DN Suchetha

## ABSTRACT

Individual identification is an important aspect in mass disasters, road accidents, air crashes, and fire accidents, where victim's bodies are mutilated beyond recognition. Forensics uses methods like anthropological, radiological, and deoxyribonucleic acid matching for identification of deceased individual's gender. Maxillary sinus, the largest air sinus of body located in the maxilla, is known to help in differentiating ethnic origin and also gender of individual. We attempted to utilize various dimensions of maxillary sinus on lateral cephalogram to establish the gender. A total of 20 male and 20 female patients of age between 25 and 40 years were recruited for the study. Dimensions of maxillary sinus were measured on lateral cephalogram using Slidex image analysis software. Dimensions of maxillary sinus within our study showed no statistically significant difference in height and length of maxillary sinus among males and females.

**Keywords:** Forensic, Gender differentiation, Lateral cephalogram, Maxillary sinus, Sex determination.

**How to cite this article:** Praveen KS, Gowda C, Kokila G, Jayadev S, Shubha k, Suchetha DN. Gender Differentiation using Maxillary Sinus. *Int J Oral Care Res* 2017;5(1):19-22.

**Source of support:** Nil

**Conflict of interest:** None

## INTRODUCTION

Identification of a decomposed, fragmented, or burnt body is a challenge for the forensic specialist. Individual identification by common physical characteristics like age, hair color, stature, etc., is commonly used. Also, in some cases, individualizing traits like tattoos will be of help in identification. In mass disasters, road accidents, air crashes, and fires where victim bodies are mutilated beyond recognition, medical forensics takes a major role in identification of the individual.<sup>1-3</sup>

<sup>1,6</sup>Senior Lecturer, <sup>2,4</sup>Reader, <sup>3</sup>Professor, <sup>5</sup>Postgraduate Student

<sup>1-3,5,6</sup>Department of Oral Pathology and Microbiology, Sri Siddhartha Academy of Higher Education, Tumkur, Karnataka India

<sup>4</sup>Department of Oral Medicine and Radiology, Sri Siddhartha Academy of Higher Education, Tumkur, Karnataka, India

**Corresponding Author:** Kunigal S Praveen, Senior Lecturer Department of Oral Pathology and Microbiology, Sri Siddhartha Academy of Higher Education, Tumkur, Karnataka, India, Phone: +919901312800, e-mail: kspraveen842@gmail.com

Identification is necessary for humanitarian and emotional reasons and for many legal issues, particularly for family members. In recent reports, identification based on dental information is considered to be highly efficient, reliable, and rapid.<sup>4-7</sup> Although many methods are followed for gender differentiation and age estimation, still identification of skeletal remains and decomposed bodies remains a difficult task in forensic medicine.

Generally, bones, such as skull, pelvis, and long bones, are used for gender identification. Unfortunately, most of the times, these bones may be in a fragmented or in incomplete state.<sup>8</sup> Hence, denser bones like maxillary sinus or zygomatic bone can be utilized for gender determination.

It is noted that although skull and other bones are badly disfigured, maxillary sinus appears to be intact.<sup>8-10</sup> Hence, it is necessary to look into the other areas of skeleton for identification of gender when the conventional methods are inconclusive.

Maxillary sinus is the largest paranasal sinus, which is pyramidal in shape, situated in the body of the maxilla.<sup>11</sup> Analysis of shape and dimension of maxillary sinus has been applied for estimation of age, gender differentiation, and also in identification of ethnic groups.<sup>8,9,12,13</sup> Within our study, we aimed to check the reliability and accuracy of using dimensions of maxillary sinus on lateral cephalogram for gender determination.

## AIMS AND OBJECTIVES

To evaluate the differences in dimensions of maxillary sinus among males and females using lateral cephalograph.

To correlate differences in dimensions among males and females to determine if it can be used for gender differentiation.

## MATERIALS AND METHODS

The sample for the study constituted patients attending the Department of Oral Medicine and Radiology, Sri Siddhartha Academy of Higher Education, Tumkur, India. Sample size consisted of 40 patients, out of which 20 were males and 20 were females of age 25 to 40 years.

### Selection Criteria

Patients with history of deleterious habits, facial asymmetry, cleft lip and palate, orthodontic treatment, orthopedic and facial asymmetry, or maxillary sinus pathology

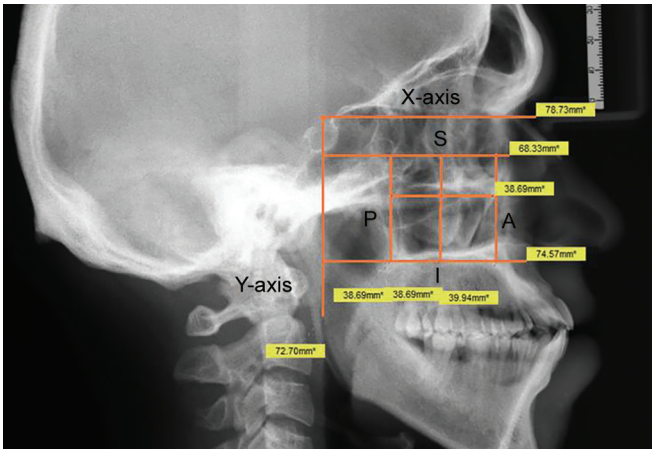


Fig. 1: Slidex image analysis software showing maxillary sinus measurements

were excluded from the study. Patients with completely erupted permanent dentition and good-quality radiographs were considered in the study.

**Procedure**

Lateral cephalogram was taken for each patient by positioning in the cephalostat with the sagittal plane of the head in vertical, the Frankfort plane in horizontal, and teeth in centric relation with head in natural head rest position. On obtaining radiographs, the maxillary sinus and cephalometric landmarks used were marked and measured using Slidex image analysis software in millimeters as shown in Figure 1.

**Method of Measurement**

- *X-axis*: Horizontal guiding plane was marked by drawing a line from midpoint of sella turcica to nasion.
- *Y-axis*: Vertical guiding plane was marked by drawing a line from midpoint of sella turcica to gnathion.

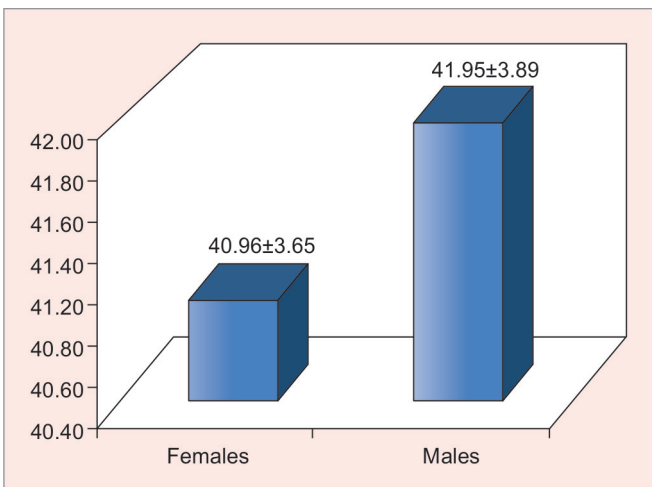
- Superior (S) and inferior (I) border of the sinus was marked by drawing lines parallel to horizontal guiding plane.
- Anterior (A) and posterior (P) borders of the sinus were marked by drawing lines parallel to vertical guiding plane.
- Height of maxillary sinus was maximum distance between superior and inferior borders.
- Length of maxillary sinus was maximum distance between anterior and posterior borders.

**RESULTS**

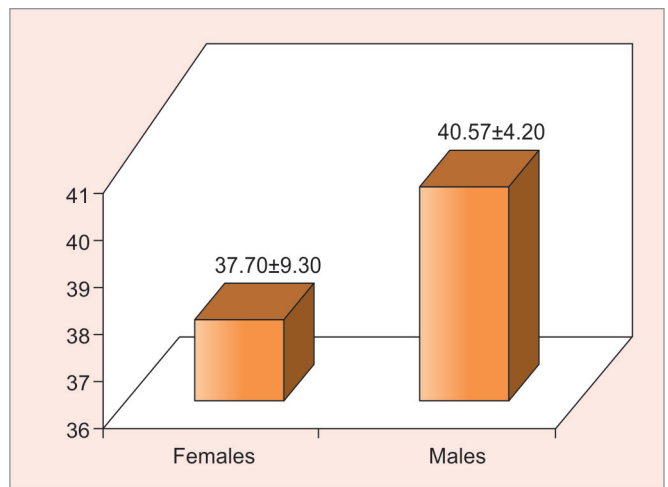
According to the present study, the mean maxillary sinus length among males is  $41.95 \pm 3.89$  and among females is  $40.96 \pm 3.65$ . This difference was not statistically significant ( $p = 0.42$ ) (Graph 1). Mean maxillary sinus height among females is  $37.7 \pm 9.30$  and males is  $40.57 \pm 4.20$ . This difference was also not statistically significant ( $p = 0.24$ ) (Graph 2). A fair correlation ( $r=0.39$ ) relationship between length and height of maxillary sinus among females was found (Graph 3), and also a fair correlation ( $r=0.39$ ) relationship between length and height of maxillary sinus among males was found (Graph 4). So, there was no statistically significant relationship between maxillary sinus length and height among males and females.

**DISCUSSION**

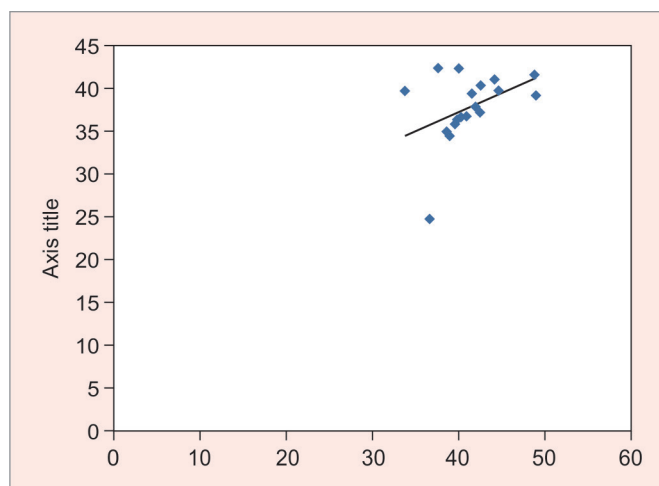
Gender determination is an essential requirement in the field of forensic medicine. Gender identification in mass disasters and in cases of skeletal remains, typically when only skull is available, is a daunting task in developing countries. The need of the hour is to develop a method, i.e., simple, less time consuming, noninvasive, and inexpensive for gender identification.



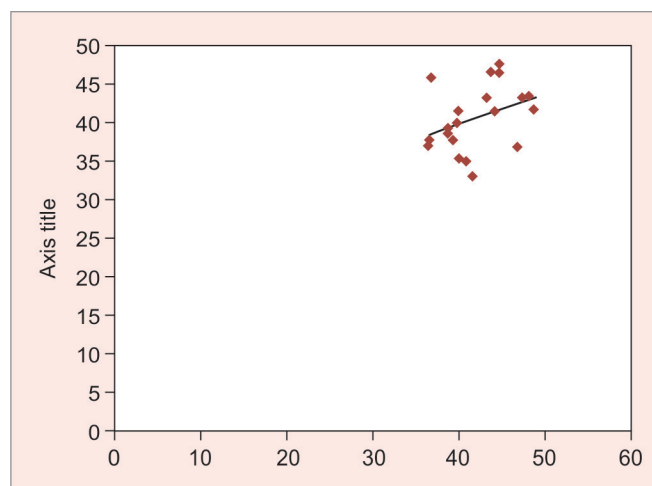
Graph 1: Mean measurement of length of maxillary sinus among males and females



Graph 2: Mean measurement of height of maxillary sinus among males and females



**Graph 3:** Fair correlation coefficient (r): 0.39 between length and height of maxillary sinus among females



**Graph 4:** Fair correlation coefficient (r): 0.36 between length and height of maxillary sinus among males

Maxillary sinus is the pneumatic space lodged in the body of maxilla, which communicates with the exterior through middle meatus.<sup>11</sup> This anatomical structure plays a vital role in reducing weight of the skull and remains intact in most deceased individuals.<sup>8,9</sup> The size of maxillary sinus depends on age,<sup>14,15</sup> which tends to stabilize after the second decade of life. It has been found that maxillary sinus areas are larger in males than in females.<sup>10</sup> The radiographic images could provide adequate measurements for maxillary sinuses that cannot be approached by other means. Maxillary sinus can be easily measured on lateral cephalogram, which is simple, less time consuming, noninvasive, and an inexpensive method for various forensic purposes. Maxillary sinus dimension measurements are valuable in studying sexual dimorphism. Hence, morphometric analysis of maxillary sinuses can assist in gender determination.<sup>16</sup> So, with this background, we designed this study for attempting gender identification by measuring maxillary sinus on lateral cephalogram.

Various studies have shown that there is significant variation in the dimension of maxillary sinus between males and females.<sup>8-10</sup> In our study, maxillary sinus measurement among males and females did not show any statistically significant difference. Similar study by Dhiman et al<sup>17</sup> showed no significant variation in maxillary sinus in males and females, whereas frontal sinus showed significant variations. Within our study, we were unable to find any statistically significant result, possibly due to two-dimensional analysis of a three-dimensional structure. So, other simpler routinely used radiographic views, such as paranasal sinus view, anteroposterior view, and orthopantomogram can be studied to check whether they can provide any sexual dimorphism of maxillary sinus measurements.

## REFERENCES

- Hill AJ, Hewson I, Lain R. The role of the forensic odontologist in disaster victim identification lessons for management. *Forensic Sci Int* 2011 Feb;205(1-3):44-47.
- Pittayapat P, Jacobs R, De Valck E, Vandermeulen D, Willems G. Forensic odontology in disaster victim identification process. *J Forensic Odontostomatol* 2012 Jul;30(1):1-12.
- Schwartz SP. Deaths in World Trade Center terrorist attacks – New York City, 2001. *MMWR Wkly* 2002 Sep;51(special issue):16-18.
- Kolude B, Adeyemi BF, Taiwo JO, Sigbeku OF, Eze UO. The role of forensic dentist following mass disaster. *Ann Ib Postgrad Med* 2010 Dec;8(2):111-118.
- Valenzuela A, Martin-de las Heras S, Marques T, Exposito N, Bohoyo JM. The application of dental methods of identification to human burn victims in a mass disaster. *Int J Legal Med* 2000;113(4):236-239.
- Pretty A, Sweet D. A look at forensic dentistry. Part I: role of teeth in the determination of human identity. *Br Dent J* 2001 Apr;190(7):359-366.
- Gnanasundaram N. Tooth for truth (The glory of forensic dentistry). *J Forensic Dent* 2010 Jul-Dec;2(2):51-52.
- Jasim HH, Al-Taei JA. Computed tomographic measurement of maxillary sinus volume and dimension in correlation to the age and gender (comparative study among individuals with dentate and edentulous maxilla). *J Bagh Coll Dent* 2013;25(1):87-93.
- Jehan M, Bhadkaria V, Trivedi A, Sharma SK. Sexual dimorphism of bizygomatic distance and maxillary sinus using CT scan. *IOSR-JDMS* 2014;13(3):91-95.
- Sidhu R, Chandra S, Devi P, Taneja N, Sah K, Kaur N. Forensic importance of maxillary sinus in gender determination: a morphometric analysis from Western Uttar Pradesh, India. *Eur J Gen Dent* 2014 Jan;3(1):53-56.
- Kumar, G.S. *Orbans oral histology and embryology*. Elsevier: 2009. p. 313.
- Fernandes CL. Forensic ethnic identification of crania: the role of the maxillary sinus – a new approach. *Am J Forensic Med Pathol* 2004 Dec;25(4):302-313.
- Ekizoglu O, Inci E, Hocaoglu E, Sayin I, Kayhan FT, Can IO. The use of maxillary sinus dimensions in gender

- determination: a thin-slice multidetector computed tomography assisted morphometric study. *J Craniofac Surg* 2014 May;25(3):957-960.
14. Jun BC, Song SW, Park CS, Lee PH, Cho KJ, Cho JH. The analysis of maxillary sinus aeration according to aging process; volume assessment by dimensional reconstruction by high-resolution CT scanning. *Otolaryngol Head Neck Surg* 2005 Mar;132(3):429-434.
  15. Barghouth G, Prior JO, Lepori D, Duvoisin B, and Schnyder P, Gudinchet F. Paranasal sinuses in children: size evaluation of maxillary, sphenoid, and frontal sinuses by magnetic resonance imaging and proposal of volume index percentile curves. *Eur Radiol* 2002 Jun;12(6):1451.
  16. Al-Azzawi AMA. Maxillary sinus area in both gender and its relation to skeletal class iii malocclusion. *Med J Babylon* 2014;10(2):20.
  17. Dhiman I, Singla A, Mahajan V, Jaj HS, Seth V, Negi P. Reliability of frontal sinus with that of maxillary sinus in assessment of different types of skeletal malocclusions. *J Indian Orthod Soc* 2015;49(2):96-103.