

CASE REPORT

Split Post and Core

¹Sidhartha SP Behera, ²Akankshita Behera, ³Pavan Preetham, ⁴Jagadeesh Naik, ⁵G Kartheek, ⁶V Shivakumar

ABSTRACT

The questions that arise during the restoration of a tooth are not new ones. The replacement of missing tooth structure has been practiced by various cultures for thousands of years. There are numerous references to the importance of healthy teeth in the Old Testament, much of which deals with the period antedating 1000 BC. No wonder then that man has made every effort to restore lost tooth structure. Attempts to restore pulpless teeth using posts have been recorded for more than 200 years. Here is where the role of posts comes into play.

Keywords: Canal, Cast, Core, Post.

How to cite this article: Behera SSP, Behera A, Preetham P, Naik J, Kartheek G, Shivakumar V. Split Post and Core. *Int J Oral Care Res* 2017;5(2):153-155.

Source of support: Nil

Conflict of interest: None

INTRODUCTION

The successful treatment of a grossly decayed tooth with pulpal disease depends not only on good endodontic therapy but also on a good prosthodontic reconstruction.¹ The primary purpose of the post is to retain a core that can be used to retain definitive prosthesis. Post and core help prevent coronal fractures when remaining coronal structure is thin. Cast post and core is indicated when there is substantial loss of coronal structure.² The following post and core systems are commonly employed to restore the endodontically treated teeth.

In prefabricated post systems, traditionally, the cast post and core has been the means of restoring teeth with insufficient remaining structure. Cast post and core is the gold standard when restoring a grossly destructed tooth.³ Prefabricated post systems are available in a variety of

materials. They are preformed posts around which a composite core is built up. Prefabricated post systems save time and can provide satisfactory results.⁴ Teeth restored with cast post and core system exhibit significantly higher fracture resistance followed by titanium and glass fiber post and core system. This can be attributed to the fact that cast post has better physic mechanical properties in comparison to prefabricated post system.⁵ If a canal requires extensive preparation, a well-adapted cast post and core restoration will be more retentive than prefabricated posts. Split cast metal post and core is indicated for multirrooted teeth with divergent roots having grossly decayed coronal structure.

CASE REPORT

A male patient aged 23 years presented to the Department of Prosthodontics with a chief complaint of a broken restoration. On examination, tooth 36 had a fractured amalgam restoration and the remaining tooth structure was minimal (Figs 1 and 2).

Treatment Plan

- Crown lengthening
- Custom made split post and core
- Restoration with a NiCr crown
- Two mm of crown lengthening (Fig. 3) was done on the lingual aspect of 36
- The post space (Fig. 4) was prepared after removal of the gutta-percha from the two mesial canals and the distal canal. Gutta-percha needed for apical seal was left in the canals.

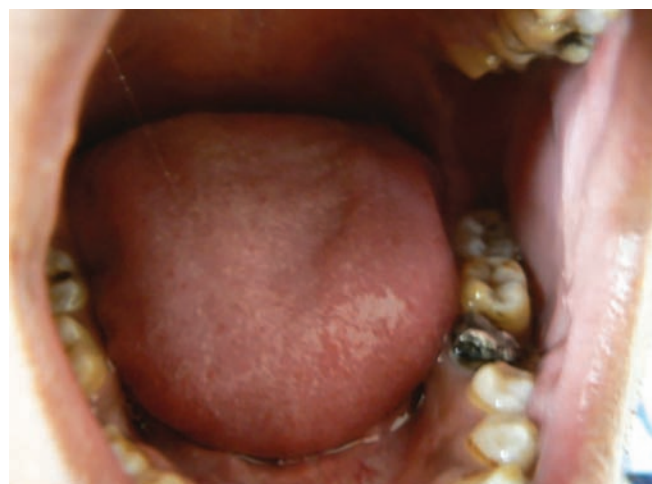

Fig. 1: Intraoral preoperative

¹Assistant Professor, ²Private Practitioner, ³⁻⁵Senior Lecturer
⁶Professor

^{1,3,4}Department of Prosthodontics, KIMS Dental College Amalapuram, Andhra Pradesh, India

²Ams Multispecialities, Bapuji Nagar, Bhubaneswar, Odisha India

⁵Department of Oral Pathology, KIMS Dental College Amalapuram, Andhra Pradesh, India

⁶Department of Periodontics, KIMS Dental College, Amalapuram Andhra Pradesh, India

Corresponding Author: Sidhartha SP Behera, Assistant Professor, Department of Prosthodontics, KIMS Dental College Amalapuram, Andhra Pradesh, India, Phone: +918147904239 e-mail: sidharth_sp@yahoo.co.in

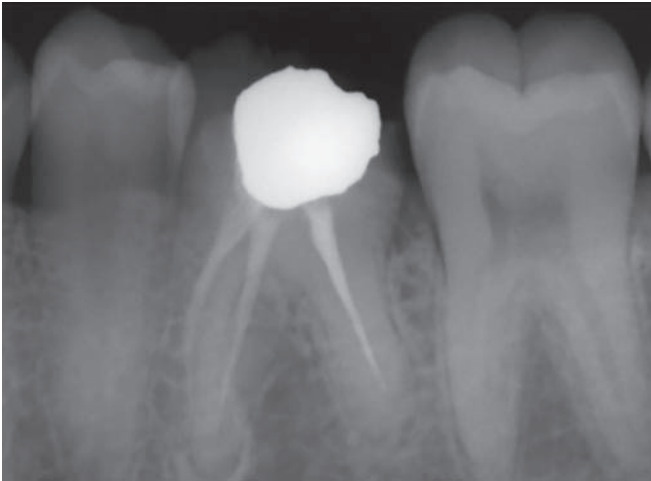


Fig. 2: Preoperative radiograph

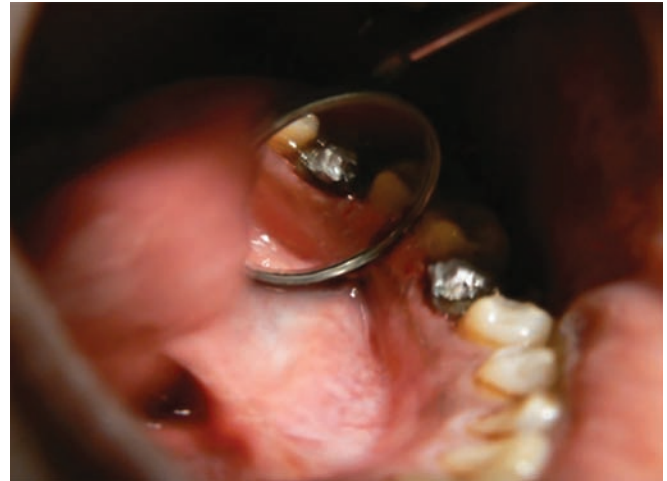

Fig. 3: Crown lengthening

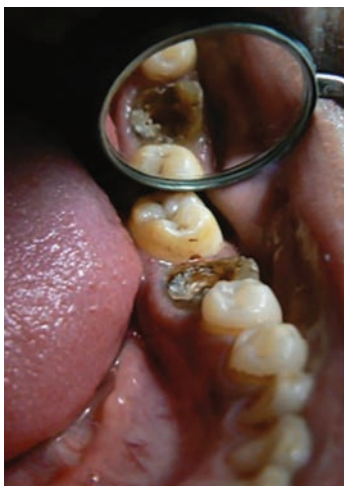

Fig. 4: Post space preparation

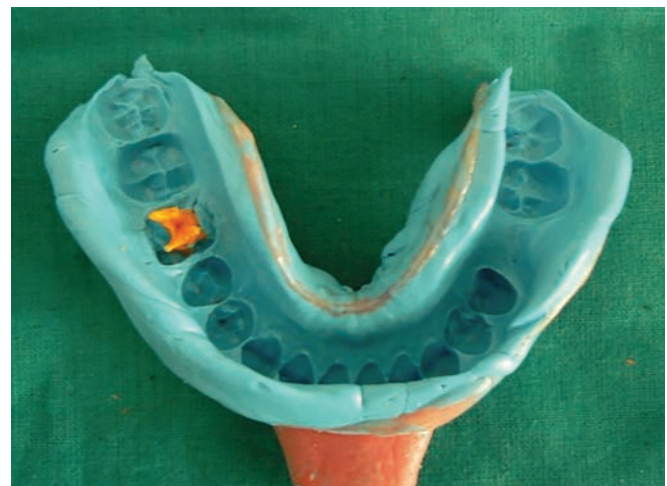

Fig. 5: Intracanal impression

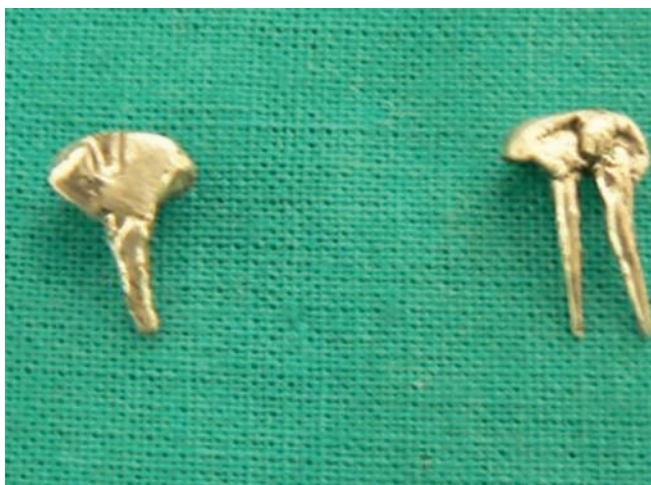

Fig. 6: Split post

- Intracanal impression (Fig. 5) was taken with light-body rubber base material using metal wires and the whole impression was picked up with medium body rubber base material (Fig. 6)

The wax pattern for distal member of the post and core was prepared with a slot and casted, later the mesial

member of the post and core was prepared with a groove and casted.

- The distal member (Fig. 7) was placed first and checked for fit; the mesial member (Fig. 8) was placed later and checked for fit. They were cemented with adhesive resin cement and final preparation was done to receive a metal crown.
- The final crown was seated and adjusted. It was then luted (Figs 9 and 10).

DISCUSSION

In cases involved with severe damage or complete loss of the coronal structure, a post is usually inserted in the root canal in order to provide sufficient retention to the core structure especially when the restored tooth is an important abutment for a fixed restoration. Multiple factors must be considered in choosing a final restoration, essential considerations include the amount of remaining sound tooth structure, occlusal function, opposing dentition, and position of the crown in the arch, as well as length, width, and area of root.⁶ Disadvantages of the

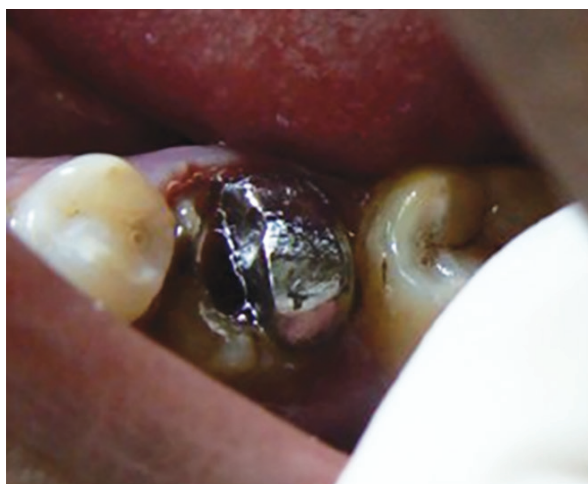

Fig. 7: Placement of distal post

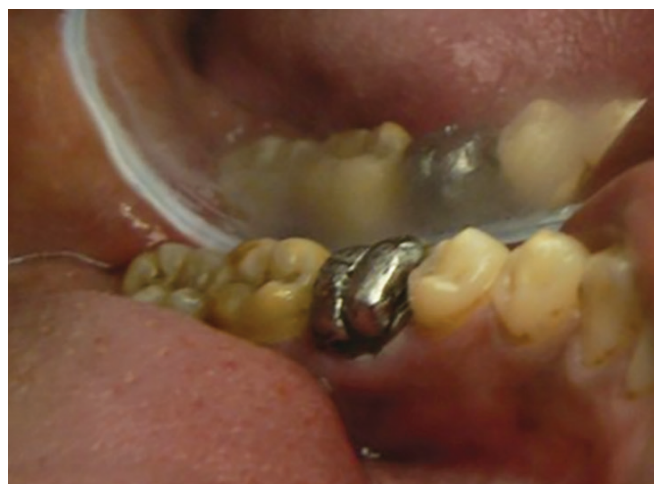

Fig. 8: Placement of mesial post

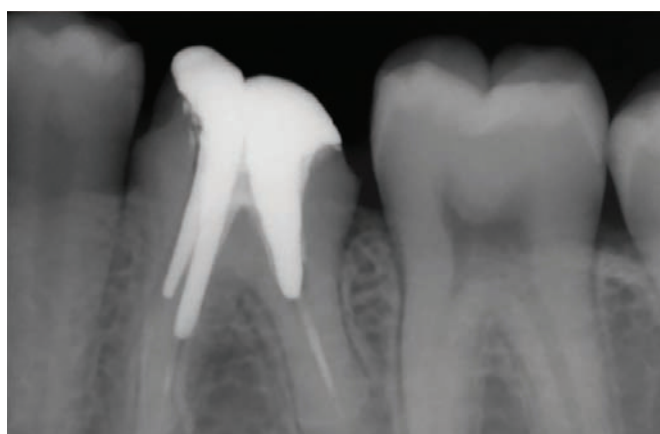

Fig. 9: Postoperative radiograph

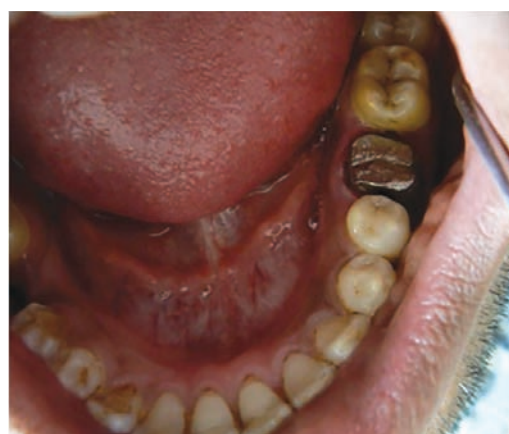

Fig. 10: Intraoral postoperative

cast metal post over fiber-reinforced composite posts have a favorable failure mode when compared with metallic posts. Various post system and post and core technique have been implemented in dentistry. The selected post and core technique must be conventional, morphologic, selective, and esthetic, and resist radicular fracture.⁷

CONCLUSION

A pulpless tooth requires a restoration that protects and conserves the remaining tooth structure. Custom-fabricated post and cores have a good long-term prognosis. Split post system reduces insertion and cementation stresses. The split may act as a vent for release of hydrostatic pressure during cementation. The clinician should be knowledgeable in selecting the right type of post and core system to meet the biological, mechanical, and esthetic needs for each tooth. An ideal post system should distribute functional stresses evenly along the root surface. Custom cast post and cores are recommended for noncircular canals when coronal tooth structure loss is moderate to severe. The

split post and core is recommended for teeth having divergent roots, with canals not allowing the path of insertion.

REFERENCES

1. Cheung W. A review of the management of endodontically treated teeth. *J Am Dent Assoc* 2005 May;136(5):611-619.
2. Chopra D, Singh NSK, Nehete P. Split cast metal post and core. *J Orofac Res* 2012;2(2):95-98.
3. Balenhol M, Wostman B, Rein C, Ferger P. Survival time of cast post and cores: a 10 year retrospective study. *J Dent* 2007 Jan;35(1):50-58.
4. Stockton LW. Factors affecting retention of post systems: a literature review. *J Prosthet Dent* 1999 Apr;81(4):380-385.
5. Kaur J, Verma PR, Nagpal A. Fracture resistance of endodontically treated teeth restored with different post systems. A comparative study. *Indian J Dent Sci* 2011;3(3):5-9.
6. Al Hashim NS, Al Moaleem MM, Al-Altas HA. Tooth coloured post system: review of literature. *Int J Contemp Dent* 2013 Apr;4(1):50-56.
7. Jhavar N, Bhondre S, Mahajan V, Dhoot R. Recent advances in post systems a review. *J Appl Dent Med Sci* 2015;1(3): 128-136.