

The Chambers of Secrets: Maxillary First Molar

¹Sushmita Shivanna, ²R Kurinji Amalavathy, ³S Prakasam

ABSTRACT

Introduction: This study is aimed to investigate the presence of second mesiobuccal (MB2) canals in first maxillary molar and to correlate findings with patient's gender and age.

Materials and methods: A total of 50 male and 50 female adult patients with age range of 15 to 35 and 36 to 60 years were divided. A detailed clinical and radiographic examination was done, and the maxillary first molar was prepared for nonsurgical endodontic therapy. In the clinical situation, the conventional radiographs were used at various stages of root canal treatment. The presence of MB2 canals was correlated with patient's age and gender.

Conclusion: An awareness and understanding of this root canal morphology can contribute to the successful outcome of root canal treatment. The prevalence of MB2 canals decreases as age increases and not much association with gender of the patient was observed.

Keywords: Canal morphology, Maxillary I molar, Mesiobuccal 2 (MB2).

How to cite this article: Shivanna S, Amalavathy RK, Prakasam S. The Chambers of Secrets: Maxillary First Molar. *Int J Oral Care Res* 2016;4(4):273-275.

Source of support: Nil

Conflict of interest: None

INTRODUCTION

A thorough knowledge of the root canal anatomy is a basic prerequisite for successful completion of the endodontic treatment.¹ Awareness and understanding of the presence of unusual external and internal root canal morphology contributes to the predictable outcome of the root canal treatment. Maxillary molars are known to have an additional canal [second mesiobuccal (MB2)] in the mesiobuccal root.² The occurrence of MB2 canal is a common variation. The frequent failure of endodontic treatment in maxillary first permanent molar teeth was likely due to the failure to locate and fill the MB2 canal.³ The failure to find and treat existing MB2 canal will decrease the long-term prognosis. Wolcott et al⁴ found in

a 5-year clinical investigation that the MB2 was located by six endodontists in 66% of first molars during retreatment, and 58% during initial treatment and in 40% of retreatments.

Stropko⁵ conducted a study on 1096 maxillary first molars over an 8-year period and concluded that MB2 canals were found in 93 and 73.2% of first molars with and without the use of surgical operating microscopes respectively. Corcoran et al⁶ reviewed MB2 location in clinical cases by three endodontic residents. The junior residents located the MB2 canal in 37% of 78 first molars and 46%, while senior residents located the MB2 in 62% of 82 first molars and 63%. Sempira and Hartwell⁷ reported that within a postgraduate endodontic program, the MB2 was found in approximately 70% of 121 maxillary first molars. The use of a surgical microscope did not result in an increase in the number of MB2 canals located in maxillary molars, compared with when the access was modified and no microscope was used.

MATERIALS AND METHODS

In our Sathyabama University Dental College and Hospital, Chennai, Tamil Nadu, India in the outpatient department of the Department of Conservative Dentistry and Endodontics, patients reported with a chief complaint in relation to maxillary first molar that needed endodontic therapy. In our study only maxillary first molar was being considered. A total of 50 male and 50 female adult patients were considered and an age group of 15 to 35 and 36 to 60 was being divided. A detailed clinical, conventional, and digital radiographic examination was done and the maxillary first molar was prepared for nonsurgical endodontic therapy. The presence of MB2 canals was correlated with patient's age and gender.

A preoperative radiograph was taken (Fig. 1). After administration of local anesthesia, tooth was isolated with a rubber dam and a conventional endodontic access opening was made (Fig. 2). After removing pulp tissue located in the chamber, three orifices were observed: Palatal, mesiobuccal, and distobuccal located in regular locations and on modification of the access, an extra orifice was located very close to the mesiobuccal orifice, which was the MB2 canal. In most of the teeth, the location of MB2 orifice opening is usually found mesial to an imaginary line between the MB1 and palatal orifices, and at about 2 to 3 mm from the MB1 orifice. The root canals were explored with a K-Flexofile ISO 10 (Dentsply Maillefer, Ballaigues, Switzerland).

¹Senior Lecturer, ²Reader, ³Professor and Head

¹⁻³Department of Orthodontics, Sathyabama University Dental College and Hospital, Chennai, Tamil Nadu, India

Corresponding Author: Sushmita Shivanna, Senior Lecturer Department of Orthodontics, Sathyabama University Dental College and Hospital, Chennai, Tamil Nadu, India, e-mail: sush317@yahoo.com

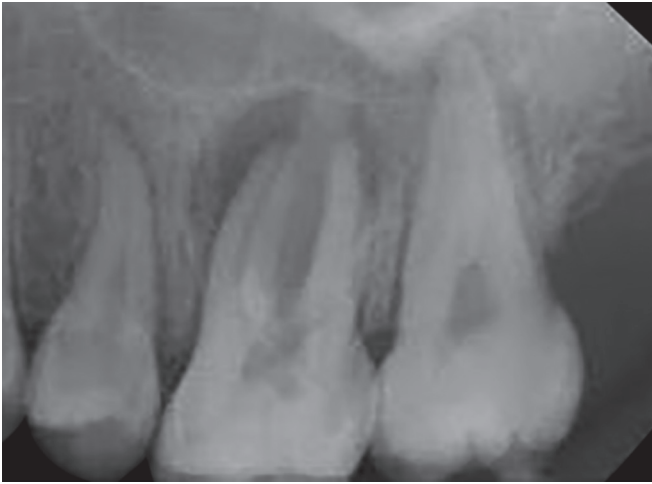


Fig. 1: Preoperative radiograph

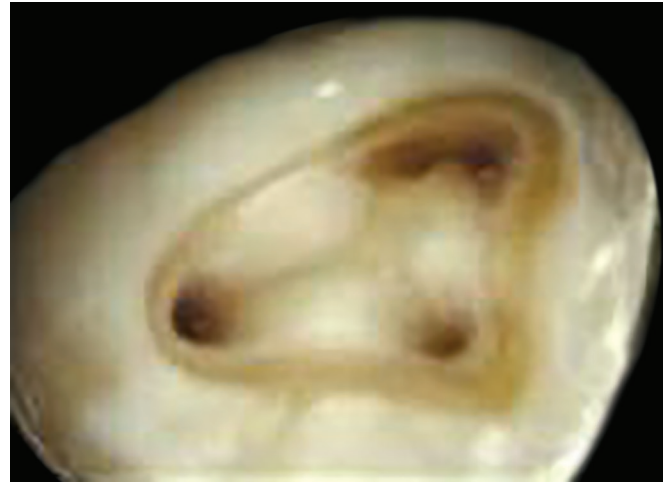


Fig. 2: Access opening

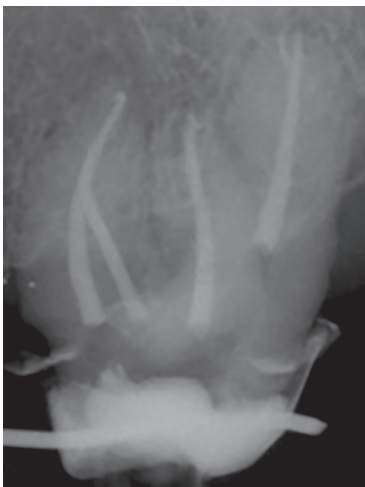

Fig. 3: Post-operative radiograph

The lengths of the canals were determined by a Root-ZX II apex locator (Morita, Tokyo, Japan) and were confirmed with a periapical radiograph of different angulation with a 15° cone shift to confirm canal configuration (Fig. 3). The canals were prepared with Protaper file system using the crown-down technique. During root canal preparation, irrigation was performed using a normal saline solution, 2.5% sodium hypochlorite solution, and 17% ethylenediaminetetraacetic acid. The canals were dried with absorbent paper points (Dentsply Maillefer, Ballaigues, Switzerland), and obturated using cold lateral compaction of gutta-percha points (Dentsply Maillefer, Ballaigues, Switzerland) and AH26® resin sealer (Dentsply Maillefer, Ballaigues, Switzerland). Postoperative radiography was used to evaluate the obturation quality (Fig. 3), followed by postendodontic restoration.

DISCUSSION

The root and root canal morphology of teeth varies greatly.⁸ Prior knowledge of root and canal anatomy

facilitates the precise detection of all root canals in a tooth during endodontic treatment. It has been shown that the total number of canals found and endodontically treated does not correspond with the number of canals actually existing in a tooth. The detection of root canals becomes difficult as a result of various factors. Age was found to have an effect on the incidence of MB2. Fewer canals were found in the MB root because of increasing age and calcification.⁹⁻¹¹ Gender and race were important factors to consider in preoperative evaluation of canal morphology. In the study of only 100 patients, each type of teeth in each gender was included. A single canal was present in mesiobuccal root in only 3% of males compared with 0% of females. However, there are conflicting results with respect to gender and number of canals.^{12,13}

It is therefore important that we understand the variables that have a direct influence on the detection and treatment of root canals. Many studies have evaluated the root canal morphology of the maxillary first molar, because this tooth presents a complex morphology that often renders treatment difficult.¹⁴ Root canal morphology should be examined further during treatment through the evaluation of radiographs taken from different horizontal angles. The use of a preoperative radiograph and additional radiographic views from a 20° mesial or distal aspect are good techniques to detect root canal morphology and anatomy.¹⁵

RESULT

In our study, the presence of the additional canal, the MB2 canal in the maxillary first molar, in the age group 15 to 35 years was more frequently located compared with the age group 36 to 60 years, which was due to increased pulpal calcification due to aging, leading to increased difficulty in locating the MB2 canal during the endodontic treatment and was significantly higher in male patients than females.

CONCLUSION

Adequate knowledge of the morphology of the root canal system and its variations is essential for optimal endodontic treatment. The operator experience plays a significant role in the location and treatment of the MB2 canal. With the use of only high-quality radiographs and with careful examination, the location of MB2 canal in the maxillary first molar was helpful so as to perform successful root canal therapy.

The frequency of the presence of an additional canal was more in younger age group (15–40 years), compared with older age group (41–70 years). The MB2 canal location was significantly higher in male patients than females.

REFERENCES

1. Krasner P, Rankow HJ. Anatomy of the pulp-chamber floor. *J Endod* 2004 Jan;30(1):5-16.
2. Chakradhar Raju RV, Sathe N, Morisetty PK, Veeramachaneni C. Endodontic management of a maxillary first molar with unusual location of second mesio buccal orifice. *J Conserv Dent* 2010 Jul;13(3):162-164.
3. Weine, FS. Initiating endodontic treatment. In: Weine, FS., editor. *Endodontic therapy*. 6th ed. St. Louis: Mosby; 2004. p. 106-110.
4. Wolcott J, Ishley D, Kennedy W, Johnson S, Minnich S. Clinical investigation of second mesiobuccal canals in endodontically treated and retreated maxillary molars. *J Endod* 2002 Jun;28(6):477-479.
5. Stropko JJ. Canal morphology of maxillary molars: clinical observations of canal configurations. *J Endod* 1999 Jun;25(6):446-450.
6. Corcoran J, Apicella MJ, Mines P. The effect of operator experience in locating additional canals in maxillary molars. *J Endod* 2007 Jan;33(1):15-17.
7. Sempira HN, Hartwell GR. Frequency of second mesiobuccal canals in maxillary molars as determined by use of an operating microscope: a clinical study. *J Endod* 2000 Nov;26(11):673-674.
8. Cleghorn BM, Christie WH, Dong CC. Root and root canal morphology of the human permanent maxillary first molar: a literature review. *J Endod* 2006 Sep;32(9):813-821.
9. Fogel HM, Peikoff MD, Christie WH. Canal configuration in the mesiobuccal root of the maxillary first molar: a clinical study. *J Endod* 1994 Mar;20(3):135-137.
10. Gilles J, Reader A. An SEM investigation of the mesiolingual canal in human maxillary first and second molars. *Oral Surg Oral Med Oral Pathol* 1990 Nov;70(5):638-643.
11. Neaverth EJ, Kotler LM, Kaltenbach RF. Clinical investigation *in vivo* of endodontically treated maxillary first molars. *J Endod* 1987 Oct;13(10):506-512.
12. Caliskan MK, Pehlivan Y, Sepetcioglu F, Turkun M, Tuncer SS. Root canal morphology of human permanent teeth in a Turkish population. *J Endod* 1995 Apr;21(4):200-204.
13. Sert S, Bayirli GS. Evaluation of the root canal configurations of the mandibular and maxillary permanent teeth by gender in the Turkish population. *J Endod* 2004 Jun;30(6):391-398.
14. Vertucci, FJ.; Haddix, JE.; Britto, LR. Tooth morphology and access cavity preparation. In: Cohen, S.; Hargreaves, KM., editor. *Pathways of the pulp*. 9th ed. St. Louis: Mosby Elsevier; 2006. p. 203.
15. Malagnino V, Gallottini L, Passariello P. Some unusual clinical cases on root anatomy of permanent maxillary molars. *J Endod* 1997 Feb;23(2):1271-28.