

AN INTERIM SILICONE AURICULAR PROSTHESIS: A CASE REPORT

Raghavendra Prasad S, * Ritika Bhambhani, ** Shalini Joshi, ***
Shruthi H R †

* Reader, Department of Prosthodontics, Sri Siddhartha Dental College, Tumkur, Karnataka, India

** Reader, Department of Prosthodontics, Gurunanak Institute of Dental Sciences and Research, Kolkata, West Bengal, India

* Professor, Department of Prosthodontics, AME's Dental College and Hospital, Raichur, Karnataka, India

† Senior Lecturer, Department of Prosthodontics, Sri Siddhartha Dental College, Tumkur, Karnataka, India

ABSTRACT

This article reports a patient with damaged right ear, for whom interim auricular silicone prosthesis was fabricated and was later convinced for a surgical autogenous reconstruction using rib graft. A male patient aged 26 years reported to Department of Prosthodontics, with a desire to improve his facial appearance. His right ear was damaged in the region of helix, since the age of five; and was lost in an accident. The hearing was normal. The following restorative options were considered- Surgical Autogenous Reconstruction, Implant retained auricular prosthesis, Silicone prosthesis retained with magnets or Silicone prosthesis retained with soft tissue undercuts and adhesives. Patient was given the option of surgical reconstruction, due to apprehension he opted for prosthetic approach. As the patient was scared of surgery, an interim auricular prosthesis was made and parallel to it patient was convinced for the permanent surgical correction. These prostheses contribute to the restoration of functional, cosmetic and psychological normalcy without the surgical intervention. It is very hard to convince the patient to go under knife, this procedure is not time consuming and reasonable and very effective in convincing the patient. The prosthesis can be used by the patient in the meantime till he gets convinced for surgery.

KEYWORDS: Ear prostheses; maxillofacial rehabilitation; room temperature vulcanizing silicone; surgical autogenous; ear reconstruction

INTRODUCTION

Human face is a well balanced imagination of the creator. The presence of all the senses and their respective sense organs is quite essential for a normal and healthy living, and it is apparent that their absence gives a challenge to an individual - functionally and psychologically.^[1] Apropos the above, Ear is the organ for auditory function and is conspicuously important for esthetics. The auricular defects can be secondary to congenital malformations, trauma or removal of neoplasm. The defects may range from complete absence (anotia); a small, malformed lobule (microtia); which could be associated with atresia of the canal. Their rehabilitation involves surgical reconstruction or prosthetic restoration. Size, etiology of the defect, and patient's concern are major attributes for treatment type.^[2,3] Surgical reconstruction is the preference in small defects, as they offer a permanent treatment and patient acceptance is better. Surgical corrections are not always possible; as in a congenitally missing ear, the complexity of reshaping the cartilage to mimic three dimensional shape of the opposite ear could present with difficulty. In cancer cases, surgery is often deferred due to concerns for recurrence. Other bottlenecks are lack of adequate soft tissue in the defect area, or patient's health precluding multiple surgical procedures required for autologous ear reconstruction. Prosthetic rehabilitation is a viable treatment alternative in these situations.^[2] Considering pros and cons of each, a multidisciplinary approach is quintessential for handling such cases. The following case report is a similar example.

MATERIALS & METHODS

A male patient aged 26 years reported to Department of Prosthodontics, with a desire to improve his facial appearance. His right ear was damaged in the region of helix, since the age of

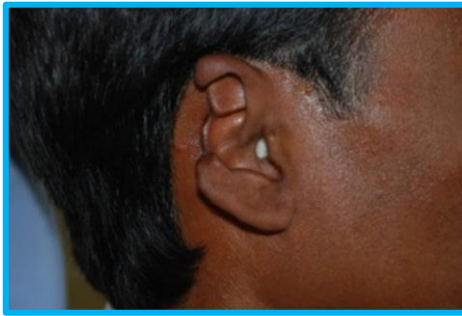

Fig. 1: Ear defect

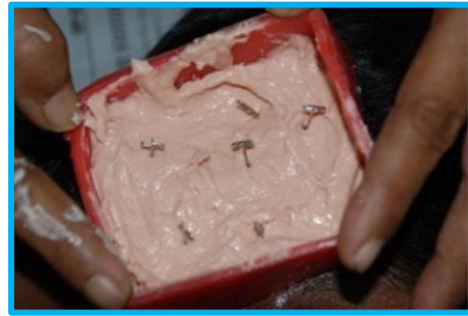

Fig. 2a: Impression making

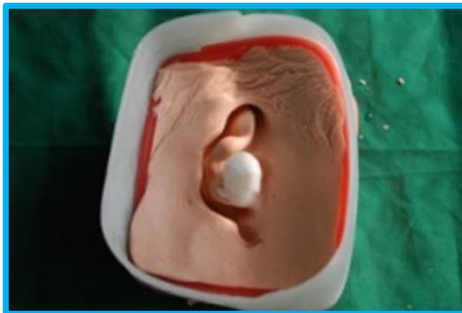


Fig. 2b: Final impression

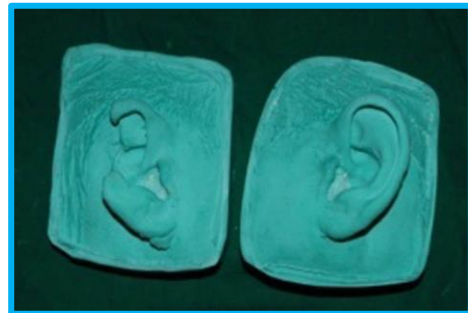


Fig. 3: Cast of both ears

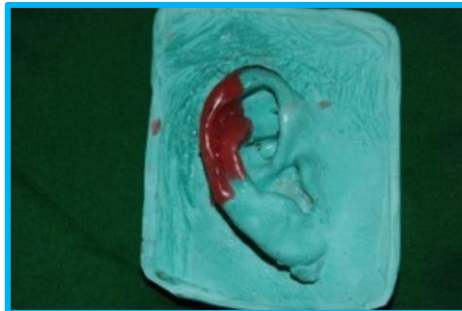

Fig. 4: Wax-up on cast

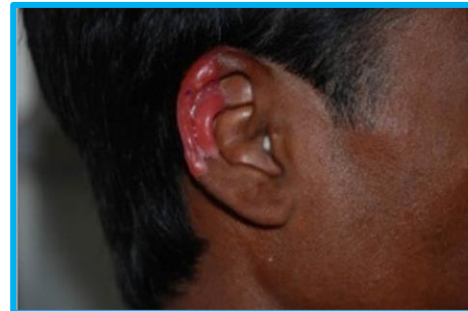

Fig. 5: Wax trail

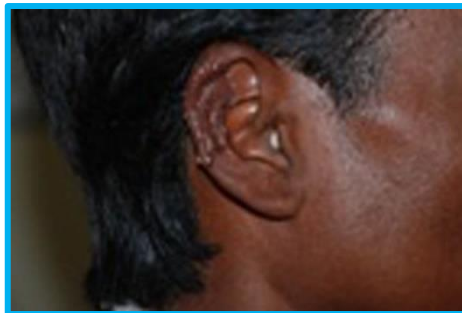

Fig. 6: Final prosthesis

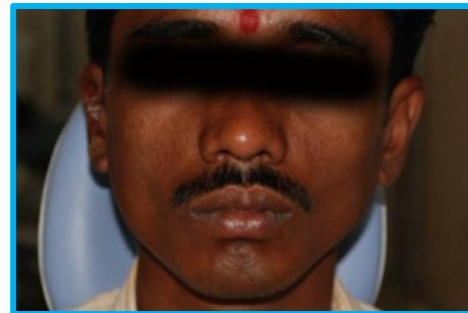

Fig. 7: Final prosthesis

five; and was lost in an accident. The hearing was normal. Patient was physically challenged, due to polio affected lower limbs, and a limping gait. He was exacting but cooperative. Patient was photographed for reference and records [Fig. 1]. The following restorative options were considered- Surgical Autogenous Reconstruction, Implant retained auricular prosthesis, Silicone prosthesis retained with magnets or Silicone prosthesis retained with soft tissue undercuts and

adhesives. Patient was given the option of surgical reconstruction, due to apprehension he opted for prosthetic approach. As the patient was scared of surgery, an interim auricular prosthesis was made and parallel to it patient was convinced for the permanent surgical correction. The patient was made to rest his head on a table at a comfortable height. The tissue beds in the auricular area are not displaceable, and therefore distortions do not result from postural changes.

Consequently the above position was chosen for making the impressions. The auricular area was confined in boxing wax, and the area prepared for impression by applying petroleum jelly. Cotton was placed in ear hole. Irreversible hydrocolloid (mixed with cool water) was used for making impression. A backing of plaster was given to provide support to the impression. Bent paper clips were used to retain it on alginate.⁴ The same procedure was followed for the normal and the defective ear one by one. Impressions were poured in dental stone and casts obtained [Fig. 2, Fig. 3]. After the casts were obtained the defective ear was reproduced in wax compared to the normal ear (mirror image technique).^[4] Appropriate changes were made in the basic contours at the next (try in) appointment, when the wax ear was positioned and adapted to the defect to achieve natural symmetry in all planes with the opposite side. Wet gauze was used to stipple the surface. Margins were feathered and pattern was luted to cast [Fig. 4, Fig. 5]. Base shade determined at the same appointment. Processing was followed similar to a conventional denture procedure. Room temperature vulcanizing silicones were used, mixed with required shades and packed in moulds obtained from above step. They were kept under clamped pressure at room temperature for a day. Later surface was characterized extrinsically for a closer shade match. Delivery of prosthesis to patient - the prosthesis was self retentive behind the ear lobule [Fig. 6, Fig. 7]. For better margin adaptation patient was instructed to use an adhesive. Patient was instructed to come for recall check-up. Considering the limitations of the prosthesis and the age of the patient, he was motivated for surgical reconstruction in future.

DISCUSSION

Prosthetic approach to treating the patients with anotia or defective ear is chosen if surgery is not permitted or unsatisfactory.^[2] Accounts of prostheses to replace the ear date back several centuries, today, aural prosthesis are made of medical grade silicone rubber and the shape and color are customized for each patient. Recent technologies use prototyping technologies (stereolithography) are other techniques of restoring the defect. These prostheses contribute to the restoration of functional, cosmetic and psychological normalcy.^[6-8] For retention tissue

adhesives or extensions in enlarged ear canal, have been used but had associated limitations. In 1995, osseointegrated implants were determined to be safe and effective for retention of maxillofacial prosthesis. They proved advantageous of positioning of the prosthesis in absence of key anatomical landmarks; or if patient lack manual dexterity or visual acuity.^[3,8,10] For the discussed case, the defective ear has been reproduced in wax compared to the normal ear contours, and was positioned and adapted to the defect to achieve natural symmetry in all planes with the opposite side. Further processing was done using a conventional flasking method, using room temperature vulcanizing silicone. The size of the defect being small was contoured well and was retained by natural undercuts and extended the prostheses full length behind the exiting ear to ensure proper retention. This proved an advantage for the patient as prosthesis was self retentive, by the existing auricle. Wax pattern could have been prepared by obtaining a wax cast from donor closely mimicking the patient or bank models. Here the mirror image technique has been used to carve it in wax.^[4, 5,9] The major challenge in the prosthesis was blending the margins with surrounding structure, from a close distance. So camouflaging can be assisted by sideburns or the residual tragus.

CONCLUSION

These prostheses contribute to the restoration of functional, cosmetic and psychological normalcy without the surgical intervention. They can bring joy to those who have been negated the surgery.

CLINICAL SIGNIFICANCE

It is very hard to convince the patient to go under knife, this procedure is not time consuming and reasonable and very effective in convincing the patient. The prosthesis can be used by the patient in the mean time till he gets convinced for surgery.

CONFLICT OF INTEREST & SOURCE OF FUNDING

The author declares that there is no source of funding and there is no conflict of interest among all authors.

BIBLIOGRAPHY

1. Patnaik VVG, Singlarajan K, Balasanju. Anatomy of a beautiful face and smile. J Anat Soc India 2003;52(1):74-80.

2. Reisberg DJ, Daw J, Dolter C MA. Ear Prosthesis and the Baha System January 2003 Audiology Online.mht
3. Reisberg DJ, Habakuk SW. Hygiene procedures for implant-retained facial prostheses. *J Prosthet Dent* 1995;74:499-502.
4. Beumer J, Curtis TA, Firtell DN. Maxillofacial rehabilitation- Prosthodontic and surgical considerations. Mosby 1979;322-9.
5. Gault D. Ear reconstruction including methodologies and outcomes, mht.
6. Ciocca L, Crescenzo F, Fantini M, Scotti R. CAD/CAM bilateral ear prostheses construction for Treacher Collins syndrome patients using laser scanning and rapid prototyping. *Computer Methods in Biomechanics and Biomedical Engineering* 2010;30(3):379-86.
7. Vadodaria S, Mowatt D, Giblin V, Gault D. Mastering ear cartilage sculpture: the vegetarian option *Plastic and Reconstructive Surgery* 2005;116(7):2043-4.
8. Bajaj Y, Wyatt M, Gault D, Bailey M, Albert DM. How we do it: BAHA positioning in patients with microtia requiring auricular reconstruction. *Clinical Otolaryngology* 2005;30:468-71.
9. Gore S, Myers S, Gault D. Mirror ear: a reconstructive technique for substantial tragal anomalies or polyotia. *Journal of Plastic, Reconstructive and Aesthetic Surgery* 2006;59:499-504.
10. Gunay Y, Erkan M, Gurbuzer B, Karayazgan B. Facilitation of facial prosthesis placement with tattoo markers: A clinical report. *J Prosthet Dent* 2007;97:256-60.