

C-SHAPED CANAL SYSTEMS: A REVIEW

Anand S, * Christalin R, ** Rejula F, *** Anulekh Babu, † Sreeja J, ††
Anupama S Gopinath †††

* Post Graduate student, Department of Conservative Dentistry and Endodontics, Government Dental College, Trivandrum, Kerala, India

** Associate Professor, Department of Conservative Dentistry and Endodontics, Government Dental College, Trivandrum, Kerala, India

*** Assistant Professor, Department of Conservative Dentistry and Endodontics, Government Dental College, Trivandrum, Kerala, India

† Assistant Professor, Department of Conservative Dentistry and Endodontics, Government Dental College, Trivandrum, Kerala, India

†† Assistant Professor, Department of Conservative Dentistry and Endodontics, Government Dental College, Trivandrum, Kerala, India

††† Assistant Professor, Department of Conservative Dentistry and Endodontics, Government Dental College, Trivandrum, Kerala, India

ABSTRACT

An important anatomic variant in root canal morphology, the C configuration presents as a thin fin connecting the canals with a predilection for mandibular second molars. Early recognition of the C-shape becomes imperative for its successful management. Newer diagnostic tools have facilitated a more precise diagnosis of this condition. Clinical and radiographic diagnoses can aid in identification and negotiation of the fan-shaped areas. The inaccessible areas and unique canal patterns make provision of optimum treatment quality a highly challenging proposition. Successful endodontic therapy of this canal configuration can be achieved with rotary and hand instrumentation assisted with ultrasonics. Three dimensional obturation of the canal system can be achieved by modifications in the conventional techniques. This article reviews the etiology, prevalence, classification, diagnosis and management of the C-shaped canal system.

KEYWORDS: Anatomic variant; c configuration; endodontic treatment

INTRODUCTION

The traditional 'one canal per root' concept is being challenged with observations from newer diagnostic tools and current scientific literature. It is therefore important to be familiar with variations in tooth anatomy to help in identification, negotiation and management of aberrant canals. An important canal variation is the "C" configuration, first mentioned in the

literature by Cooke and Cox.^[1] In contrast to normal anatomy, the orifice of a C-shaped canal is ribbon-shaped and transcribes an arc of 180°. The feature usually starts at mesiolingual line angle of the chamber, curves buccally and ends at the distal aspect.^[1] Below the orifice level, the root structure can be basically divided into two groups.

1. With three or more distinct canals below the orifice.
2. With single, ribbon-like, C-shaped canal from orifice to apex.

C-shaped canals often present a challenge in debridement and obturation. Roots of this type of teeth may be fused in buccal or lingual aspect and may have a conical or square configuration.^[2-4] Fins or webs may be seen connecting individual root canals. This review will address the etiology, classification, prevalence, diagnosis and management of C-shaped canals.

ETIOLOGY

The most accepted theory for the formation of C-shaped canal configuration is the failure of Hertwig's epithelial root sheath (HERS) to fuse on the buccal or lingual root surface.^[5] This results in a conical or prism shaped root with a thin interradicular ribbon-shaped isthmus connecting them.^[3,6,7] Manning attributed the formation of C-shaped roots to age changes like deposition of cementum. This theory was however contested since separate canals in roots with C-shaped anatomy were observed even in patients under 40 years of age.^[3,8] With the documentation of racial predilection, a genetic basis for C-shaped canals has also been proposed.^[3,9] The C-shape may be continuous

throughout the root length, or two/three canals may be found in the C-shaped groove.^[7,10]

CLASSIFICATION

A comprehensive classification of C-shaped canal system is essential for its diagnosis and management.^[4]

Melton's Classification

Melton *et al.*,^[11] in 1991 proposed the following classification of C-shaped canals based on their cross-sectional shape (Fig. 1).

Category I: continuous C-shaped canal running from the pulp chamber to the apex defines a C-shaped outline without any separation (C1).

Category II: the semicolon-shaped (;) orifice in which dentine separates a main C-shaped canal from one mesial distinct canal (C2).

Category III: refers to those with two or more discrete and separate canals:

- Subdivision I: C-shaped orifice in the coronal third that divides into two or more discrete and separate canals that join apically.
- Subdivision II: C-shaped orifice in the coronal third that divides into two or more discrete and separate canals in the midroot to the apex.
- Subdivision III: C-shaped orifice that divides into two or more discrete and separate canals in the coronal third to the apex (C3).

Fan's Classification (Anatomic classification)

Fan *et al.*,^[4] in 2004 modified Melton's classification into the following categories.

1. Category I (C1): uninterrupted "C" with no separation or division (Fig. 1A).
2. Category II (C2): the canal shape resembled a semicolon resulting from a discontinuation of the "C" outline (Fig. 1B), but either angle α or β (Fig. 2) should be no less than 60° .
3. Category III (C3): 2 or 3 separate canals (Fig. 1C and D) and both angles, α and β , were less than 60° (Fig. 3).
4. Category IV (C4): only one round or oval canal in that cross section (Fig. 1E).
5. Category V (C5): no canal lumen could be observed (which is usually seen near the apex only) (Fig. 1F)

The morphology orifice is not a good predictor of the actual canal anatomy as the "C" shape may vary along the root length. In this classification,

one of the canals in the C2 category with $\beta \geq 60^\circ$ (Fig. 2) would extend into the fused area of the root where the dentin wall may be quite thin and are more difficult to clean and shape than C3 canals.

Fan's classification (Radiographic classification)

Fan *et al.*,^[12] classified C-shaped roots according to their radiographic appearance into three types.

1. Type I: conical or square root with a vague, radiolucent longitudinal line separating the root into distal and mesial parts. Mesial and distal canals merged into one before exiting at the apical foramen (Fig. 4A).
2. Type II: conical or square root with a vague, radiolucent longitudinal line separating the root into distal and mesial parts. Mesial and distal canals continue on their own pathway to the apex (Fig. 4B).
3. Type III: conical or square root with a vague, radiolucent longitudinal line separating the root into distal and mesial parts. Of the mesial and distal canals, one canal curved to and superimposed on this radiolucent line when running toward the apex, and the other canal continued on its own pathway to the apex (Fig. 4C).

Classification of pulp chamber floor^[13]

1. Type I: a peninsula-like floor with a continuous C-shaped orifice.
2. Type II: a buccal, strip-like dentin connection exists between the peninsula-like floor and the buccal wall of the pulp chamber that separates the C-shaped groove into mesial (M) and distal (D) orifices. Sometimes the mesial orifice separates into a mesiobuccal (MB) and a mesiolingual (ML) orifice by another strip-like dentin between the peninsula-like floor and the mesial wall of the pulp chamber.
3. Type III: only one mesial, strip-like dentin connection exists between the peninsula-like floor and the M wall, which separates the C-shaped groove into a small ML orifice and a large MB-D orifice. The MB-D orifice was formed by the merging of the MB orifice and the D orifice.
4. Type IV: Non-C-shaped floor. One distal canal orifice and one oval or two round mesial canal orifices are present.

PREVALENCE

Ethnic variations exist in the prevalence of this

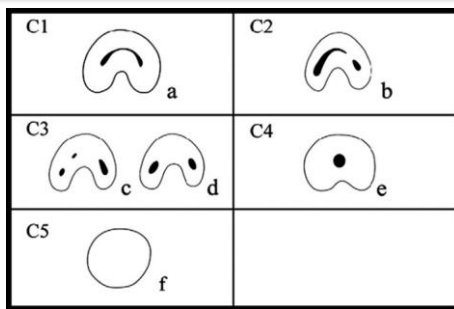


Fig. 1: Classification of C-shaped canal configuration

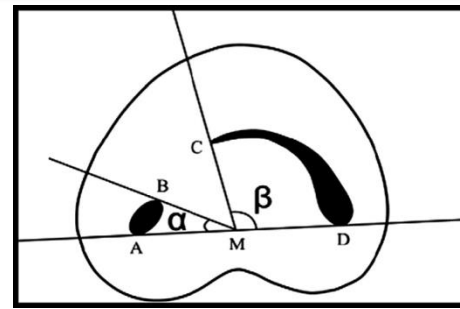


Fig. 2: Measurement of angles for the C2 canal

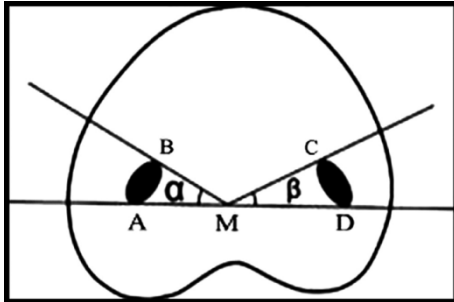


Fig. 3: Measurement of angles for the C3 canal

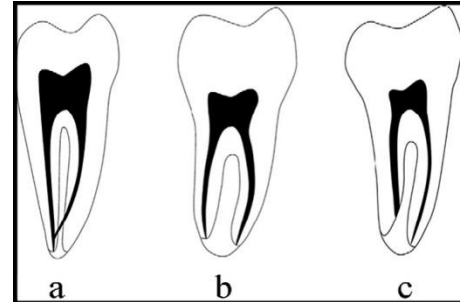


Fig. 4: Measurement of angles for the C2 canal

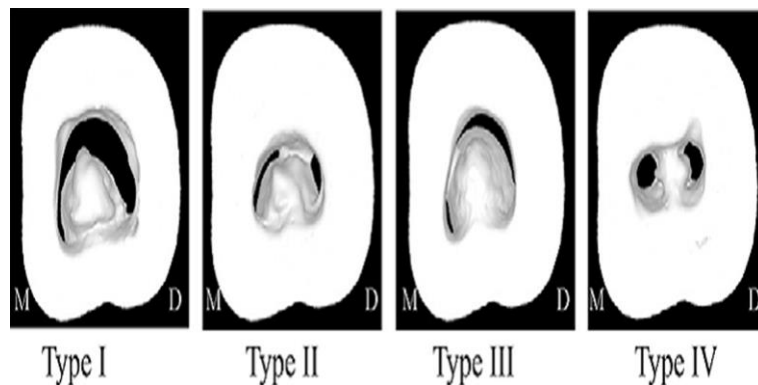


Fig. 4: Radiographic types. (A) Type I, (B) type II, and (C) type III

condition. No correlation has been reported with gender, age or tooth position. Studies in Chinese and Lebanese populations have shown a preponderance of this condition in mandibular second molars.^[3,6,14-16] The C-shaped anatomy has been found to be more common in Asians than in whites.^[17] The Burmese population presented a prevalence of 22.4%, much higher than the Indian (7.5%), Thai or Sri Lankan population.^[18-24] Despite its high occurrence in mandibular second molars,^[2,25,26] this variation has also been reported in mandibular^[25] and maxillary first molars (0.12%),^[26,27] maxillary (4.7%) and mandibular third molars (3.5%-4%), mandibular first and second premolars (1%)^[28-31] and even in maxillary lateral incisors.^[32] Bilateral incidence of C-shaped canals has been reported in 70%-81%^[33,34] of cases. Singla & Aggarwal reported

this configuration in the palatal canal of a maxillary second molar.^[35]

DIAGNOSIS

It is imperative to diagnose the C-shaped canal prior to initiating endodontic treatment considering the difficulties that can be encountered in canal shaping and obturation.^[36]

Clinical Diagnosis

The crown morphology does not show special features that can aid in the diagnosis of teeth with C-shaped anatomy. Clinical recognition of C-shaped canals is based on the anatomy of the floor of the pulp chamber and the persistence of hemorrhage.^[37] The pulp chamber of teeth with C-shaped canals is usually large apico-occlusally with a corresponding apically located bifurcation. Several orifices may be probed that link up on further instrumentation.^[1] An instrument can be passed from mesial to distal aspect without

obstruction in a true C-shaped canal. Dentin bridges impede such passage in other configurations.^[11] In cases with a separate canal and a buccal or lingual C-shaped canal, an instrument inserted into any side of the C ends in the distal foramen of the tooth. This instrument can probe the complete extension of the C.^[38] The canal is separate if the instrument cannot be passed through the isthmus of the pulpal floor. Fan *et al.*,^[4] stated that for a mandibular second molar to qualify as having a C-shaped canal system, it has to exhibit all the following three features:

- a. Fused roots.
- b. A longitudinal groove on lingual or buccal surface of the root.
- c. At least one cross-section of the canal should belong to the C1, C2, or C3 configuration, as per Fan's anatomic classification.

The first diagnostic indication of C-shaped roots may be localized periodontal disease predisposed by narrow root grooves on the buccal or lingual surface.^[6,11] A separate root canal exiting at the apical level should be suspected when the orifice looks connected at the subpulpal level.^[39]

Radiographic Diagnosis

The simplest, noninvasive clinical method to provide a clue about the canal morphology is a preoperative periapical radiograph and an angulated radiograph from 20° mesial or distal projection.^[4,40] Cooke & Cox,^[11] opined that it is impossible to diagnose C-shaped canals from preoperative periapical radiographs. Haddad *et al.*^[6] in their review suggested that preoperative radiographs revealed many similar characteristics such as radicular fusion, radicular proximity, a large distal canal or a blurred image of a third canal in between, which allowed the prediction of C-shaped canal.^[6,8] Working length radiographs of C-shaped canals may show two characteristics: instruments converging at the apex and/or may exit at the furcation resembling a furcal perforation.^[2,10,11,37] This appearance occurred more in category I (continuous).^[2] Interpretation of more than one radiograph or use of an apex locator gives a differential diagnosis of C-shaped molars from furcation perforation.^[11,14] Film combinations - "preoperative and working length radiographs" or "preoperative and final radiographs" or "all three radiographs" make radiographic interpretation more effective than

single radiographs in diagnosing the C-shape. Working length radiographs are more helpful while preoperative radiographs are least effective.^[41] Newer imaging modalities like spiral CT^[42] and micro CT^[13] aid in the diagnosis of C-shaped canals. Both are time consuming and have limited application in in-vivo studies, however. Limited - volume CBCT with low radiation dose and high resolution, on the other hand, is a precise and nondestructive technique which allows for both qualitative and quantitative evaluation of root canal morphology in three dimensions. Further, it gives greater diagnostic data with reduction of subjectivity in interpretation, as the problem of overlap, common in two dimensional views is eliminated.^[33,43,33]

MANAGEMENT

The C-shaped configuration presents a complex canal anatomy. This makes it difficult to clean and seal the irregular areas which contain infected debris or soft-tissue remnants. Many modified techniques have been proposed to accomplish meticulous cleaning and shaping for a successful root canal treatment.^[45] The associated challenges can arise during diagnosis to instrumentation, obturation, and post space preparation.^[2]

Location and negotiation of canals

After achievement of endodontic access and removal of tissue from the pulp chamber, modifications in the access design facilitates location and negotiation of the complete canal system.^[46] If the orifice morphology is a continuous C-shape or an arc-like mesiobuccal-distal pattern, the numbers of canals vary from one to three. When the outline is round, there is usually only one canal below the orifice. The number of canals can be one or two, in an oval or flat orifice.^[47] For continuous C-shaped orifice, three files are inserted, one in the middle and one at either end. With oval orifices, two files are inserted, one at each end of the orifice. One file is inserted when the orifice is round.^[47] Calcifications in the pulp chamber can conceal the C-shape. The orifices have to be probed which link up on further instrumentation.^[19] Canals may be missed because of bifurcation, dentin fusion, and curvatures.^[47] These irregularities should be explored with small size endodontic files - #8, #10 or #15 K-files.^[13] The root canal system in C-shaped canals appear as a dark line or area under fiber optic transillumination.^[2] Surgical operating

microscope is an important adjunct in successfully treating such canals.^[17,26]

Cleaning and shaping

In most situations, the mesiobuccal and distal canal spaces can be prepared utilizing a conventional approach. Instrumentation of the isthmus above #25 size files should be avoided to minimize the potential for strip perforation. The orifice portion of the slit can be widened with Gates Glidden drills to access all the irregularities.^[48] For narrow, interconnecting isthmus areas as in C1 (continuous C type) and C2 (semicircular type) configurations, Gates Glidden drills should not be used and cleaning should be carried out using #25 or smaller instruments, with copious irrigation using 5.25% sodium hypochlorite.^[2,49] Abou-Rass *et al.*, recommended anti-curvature filing technique to avoid danger zones.^[50] Perforation of the thinner lingual walls can be minimized by instrumentation directed buccally.^[2] Apical instrumentation should be limited to #30(0.06 taper).^[51] Following rotary instrumentation, filing using K-files or H-files may be specifically directed towards the isthmus areas to obtain better debridement.^[52] The recently developed self-adjusting file (SAF) system is more efficacious than the protaper system for shaping C-shaped canals.^[53] Intracanal instruments are unable to access and debride the entire portion of the large canal space, making the role of irrigation more relevant.^[14] Canal irrigation techniques incorporating ultrasonics is more effective in achieving adequate debridement.^[51] Deeper penetration with small instruments and increased volume of irrigant allows more cleansability in fan-shaped areas of the C-shaped canal.^[11] However, injudicious ultrasonic instrumentation carries the risk of perforation.^[2] In C-shaped molars with a single apex, the mesiolingual canal is separate and shorter than the other canals. The mesiobuccal canal swings back and merges with the distal canal and exits through a single foramen. This feature can result in over instrumentation of the mesiolingual canal. A few molars with C-shaped orifices have mesiobuccal and distal canals that do not merge and have separate portals of exit.^[17]

Obturation

The intricacies in canal morphology necessitate variations from the traditional methods of

obturation. For placement of the master cones in C-shaped canals, Barnett^[7] recommended a large diameter file to be seated in the distal canal before placing the master cone in the mesial canal. The file is then withdrawn, master cone seated in distal canal, followed by placement of accessory cones in the middle portion of the C-shaped canal. Sealing the buccal isthmus is difficult using lateral condensation alone, as the isthmus cannot be prepared with a flare to permit deeper placement of the spreader. This makes application of gutta-percha, thermoplasticized with electric spreaders or spreaders heated in an open flame or delivered by injectable systems more appropriate.^[54] The quality of obturation is considerably compromised as the hydraulic forces can dramatically decrease because of the unshaped divergent areas, which may offer resistance to the flow of obturating material and communications between the main canals of the C-shape through which the entrapped filling materials may pass from one canal to another. Regardless of the choice of obturation technique, proper placement of sealer with ultrasonic endodontic files is critical.^[2,17,55] The technique developed by Walid tries to overcome these problems^[48] by the simultaneous use of two pluggers to down pack the main canals in a C-shaped canal. Two fine-medium cones were seated in the mesiolingual and distal canals. No accessory cones should be placed in the fin between them and a medium point was fitted in the mesiobuccal canal. Three pluggers are used for obturation. Using Touch'N Heat (Sybron Endo/Analytic, Irvine, CA) gutta-percha at the mesiolingual orifice level was seared off where the largest plugger was placed, while down packing the distal canal with the smallest plugger. While packing the mesiolingual canal, the smallest plugger used in the distal canal was held in place. The resistance toward the passage of obturating material from one canal to another was increased by placing two master points and blocking the canal entrance with a plugger. Ordinola- Zapata *et al.*,^[56] in their study using Maggiore's modified MicroSeal technique found that the apical third was less accurately filled and concluded that C2 canals with a 120° or 150° is more difficult to fill than a 60° angle C2 canal. Martin^[57] developed the EndoTec II (Medidenta, Inc., Woodside, NY) that combined the qualities

of both the ease and speed of lateral compaction as well as the superior density gained by vertical compaction of warm gutta-percha. Using the “zap and tap” maneuver, improved compaction could be achieved while obturating a C-shaped canal by using the device(45). This involves heating the EndoTec plugger for 4 to 5 seconds (zap) followed by moving the hot instrument in and out in short continuous strokes (tap) 10 to 15 times.

Post endodontic restorations

The thin dentin cross section between the external surface of the root and the internal canal system can compromise the structural integrity of these teeth.^[11] The available undercuts of the deep pulp chamber provide ample retention.^[2,7] Bonded amalgam or composite is the preferred core buildup material for such teeth.^[48,51] For resistance to root fracture, at least 1 mm of sound tooth structure should be present around a post.^[58] None of the prepared canals had a canal wall more than 1 mm thickness at the furcation.^[51] Prefabricated or cast posts have a risk of creating a strip perforation.^[11] No prefabricated post (circular or conical) would fit the C-shaped canals.^[48,51] Post placement is preferred in the tubular distal canal to facilitate adaptation and stress distribution. Placement of posts or anti-rotational pins in the mesiolingual and mesiobuccal areas of C-shaped root can cause perforation.

Endodontic Surgery

Hemisection or root amputation is contraindicated pertaining to the absence of furca. The intercanal communications or fins make retro-preparation and retro-filling after apicoectomy extremely difficult. If surgical intervention is indicated for a molar with C-shaped root canal anatomy, extraction followed by extra oral retro filling and intentional replantation(1) should be considered.

Prognosis

A suspicion of furcal breakdown should be kept in mind and evaluated in the follow-up radiographs since it is the most difficult area to obturate and is associated with the greatest risk of perforation. Furcal failures have a poor prognosis.

CONCLUSION

The intricacies present in the C-shaped anatomy pose a challenge during negotiation, debridement and obturation. However, with advances in the tools for diagnosis and treatment, the condition should no longer be an enigma for the clinician.

The advent of rotary and hand instrumentation assisted with ultrasonics as well as modified obturation techniques have improved the prognosis of this anatomical variant. It is appropriate to observe cautious optimism in the success of the root canal treatment of a C-shaped canal.

CONFLICT OF INTEREST & SOURCE OF FUNDING

The author declares that there is no source of funding and there is no conflict of interest among all authors.

BIBLIOGRAPHY

1. Cooke III HG, Cox FL. C-shaped canal configurations in mandibular molars. *J Am Dent Assoc.* 1979;99(5):836-9.
2. Jerome CE. C-shaped root canal systems: diagnosis, treatment, and restoration. *Gen Dent* 1994;42(5):424.
3. Manning SA. Root canal anatomy of mandibular second molars. *Int Endod J* 1990;23(1):40-5.
4. Fan B, Cheung GS, Fan M, Gutmann JL, Bian Z. C-shaped canal system in mandibular second molars: part I - anatomical features. *J Endod* 2004;30(12):899-903.
5. Orban B, Mueller E. The development of the bifurcation of multirooted teeth. *J Am Dent Assoc* 1922;16(2):297-319.
6. Haddad GY, Nehme WB, Ounsi HF. Diagnosis, classification, and frequency of C-shaped canals in mandibular second molars in the Lebanese population. *J Endod* 1999;25(4):268-71.
7. Barnett F. Mandibular molar with C-shaped canal. *Dent Traumatol* 1986;2(2):79-81.
8. Al-Fouzan KS. C-shaped root canals in mandibular second molars in a Saudi Arabian population. *Int Endod J* 2002;35(6):499-504.
9. Fischischweiger W, Clausnitzer E. Root formation in molar teeth of the CD-1 mouse. *J Endod* 1988;14(4):163-8.
10. Barril I, Cochet JY, Ricci C. [Treatment of a canal with a “ C” configuration]. *Rev Francaise Endod Publ Off Soc Francaise Endod* 1989;8(3):47-58.
11. Melton DC, Krell KV, Fuller MW. Anatomical and histological features of C-

- shaped canals in mandibular second molars. *J Endod* 1991;17(8):384-8.
12. Fan B, Cheung GS, Fan M, Gutmann JL, Fan W. C-shaped canal system in mandibular second molars: Part II - Radiographic features. *J Endod* 2004;30(12):904-8.
 13. Min Y, Fan B, Cheung G, Gutmann J, Fan M. C-shaped Canal System in Mandibular Second Molars Part III: The Morphology of the Pulp Chamber Floor. *J Endod* 2006;32(12):1155-9.
 14. Weine FS, Pasiewicz RA, Rice RT. Canal configuration of the mandibular second molar using a clinically oriented in vitro method. *J Endod* 1988;14(5):207-13.
 15. Walker RT. Root form and canal anatomy of mandibular second molars in a southern Chinese population. *J Endod* 1988;14(7):325-9.
 16. Yang ZP, Yang SF, Lin YC, Shay JC, Chi CY. C-shaped root canals in mandibular second molars in a Chinese population. *Dent Traumatol* 1988;4(4):160-3.
 17. Cohen S, Burns RC. *Pathways of the pulp* 8th ed. St Louis Mosby. 2002;2.
 18. Gulabivala K, Aung TH, Alavi A, Ng YL. Root and canal morphology of Burmese mandibular molars. *Int Endod J* 2001;34(5):359-70.
 19. Gulabivala K, Opananon A, Ng YL, Alavi A. Root and canal morphology of Thai mandibular molars. *Int Endod J* 2002;35(1):56-62.
 20. Peiris R, Takahashi M, Sasaki K, Kanazawa E. Root and canal morphology of permanent mandibular molars in a Sri Lankan population. *Odontology*. 2007;95(1):16-23.
 21. Peiris HRD, Pitakotuwage TN, Takahashi M, Sasaki K, Kanazawa E. Root canal morphology of mandibular permanent molars at different ages. *Int Endod J* 2008;41(10):828-35.
 22. Neelakantan P, Subbarao C, Subbarao CV, Ravindranath M. Root and canal morphology of mandibular second molars in an Indian population. *J Endod* 2010;36(8):1319-22.
 23. Velmurugan N, Sandhya R. Root canal morphology of mandibular first premolars in an Indian population: a laboratory study. *Int Endod J* 2009;42(1):54-8.
 24. Sandhya R, Velmurugan N, Kandaswamy D, others. Assessment of root canal morphology of mandibular first premolars in the Indian population using spiral computed tomography: an in vitro study. *Indian J Dent Res* 2010;21(2):169.
 25. Bolger WL, Schindler WG. A mandibular first molar with a C-shaped root configuration. *J Endod* 1988;14(10):515-9.
 26. Yilmaz Z, Tuncel B, Serper A, Calt S. C-shaped root canal in a maxillary first molar: a case report. *Int Endod J* 2006;39(2):162-6.
 27. Dankner E, Friedman S, Stabholz A. Bilateral C shape configuration in maxillary first molars. *J Endod* 1990;16(12):601-3.
 28. Lu TY, Yang SF, Pai SF. Complicated root canal morphology of mandibular first premolar in a Chinese population using the cross section method. *J Endod* 2006;32(10):932-6.
 29. Sidow SJ, West LA, Liewehr FR, Loushine RJ. Root canal morphology of human maxillary and mandibular third molars. *J Endod* 2000;26(11):675-8.
 30. Kuzekanani M, Haghani J, Nosrati H. Root and canal morphology of mandibular third molars in an Iranian population. *J Dent Res Dent Clin Dent Prospects* 2012;6(3):85.
 31. Cleghorn BM, Christie WH, Dong CC. Root and root canal morphology of the human permanent maxillary first molar: a literature review. *J Endod* 2006;32(9):813-21.
 32. Bóveda C, Fajardo M, Millán B. Root canal treatment of an invaginated maxillary lateral incisor with a C-shaped canal. *Quintessence Int Engl Ed*. 1999;30:707-11.
 33. Zheng Q, Zhang L, Zhou X, Wang Q, Wang Y, Tang L, *et al*. C-shaped root canal system in mandibular second molars in a Chinese population evaluated by cone-beam computed tomography. *Int Endod J* 2011;44(9):857-62.
 34. Sabala CL, Benenati FW, Neas BR. Bilateral root or root canal aberrations in a dental school patient population. *J Endod* 1994;20(1):38-42.
 35. Singla M, Aggarwal V. C-shaped palatal canal in maxillary second molar mimicking two palatal canals diagnosed with the aid of

- spiral computerized tomography. *Oral Surg Oral Med Oral Pathol Oral Radiol Endodontology* 2010;109(6):92-5.
36. Benenati FW. Mandibular second molar with C-shaped canal morphology and five canals: report of a case. *Gen Dent* 2003;52(3):253-4.
 37. Xu X, Wang DG, Wang XY. [Clinical significance of the abnormal radiographic manifestations of pulp cavity]. *Shanghai Kou Qiang Yi Xue Shanghai J Stomatol* 1996;5(2):85-6.
 38. Ricucci D, Pascon EA, Langeland K. Long-term follow-up on C-shaped mandibular molars. *J Endod* 1996;22(4):185-7.
 39. Seo MS, Park DS. C-shaped root canals of mandibular second molars in a Korean population: clinical observation and in vitro analysis. *Int Endod J* 2004;37(2):139-44.
 40. De Moor RJG. C-shaped root canal configuration in maxillary first molars. *Int Endod J* 2002;35(2):200-8.
 41. Lambrianidis T, Lyroudia K, Pandelidou O, Nicolaou A. Evaluation of periapical radiographs in the recognition of C-shaped mandibular second molars. *Int Endod J* 2001;34(6):458-62.
 42. Cimilli H, Cimilli T, Mumcu G, Kartal N, Wesselink P. Spiral computed tomographic demonstration of C-shaped canals in mandibular second molars. *Dentomaxillofacial Radiol* [Internet]. 2014 [cited 2015 Sep 14]; Available from: <http://www.birpublications.org/doi/full/10.1259/dmfr/64778606>
 43. Soğur E, Gröndahl HG, Baksı BG, Mert A. Does a combination of two radiographs increase accuracy in detecting acid-induced periapical lesions and does it approach the accuracy of cone-beam computed tomography scanning? *J Endod* 2012;38(2):131-6.
 44. Cotton TP, Geisler TM, Holden DT, Schwartz SA, Schindler WG. Endodontic applications of cone-beam volumetric tomography. *J Endod* 2007;33(9):1121-32.
 45. Liewehr FR, Kulild JC, Primack PD. Obturation of a C-shaped canal using an improved method of warm lateral condensation. *J Endod* 1993;19(9):474-7.
 46. Kottoor J, Velmurugan N, Ballal S, Roy A. Four-rooted maxillary first molar having C-shaped palatal root canal morphology evaluated using cone-beam computerized tomography: a case report. *Oral Surg Oral Med Oral Pathol Oral Radiol Endodontology* 2011;111(5):41-5.
 47. Fan B, Min Y, Lu G, Yang J, Cheung GS, Gutmann JL. Negotiation of C-shaped canal systems in mandibular second molars. *J Endod* 2009;35(7):1003-8.
 48. Walid N. The use of two pluggers for the obturation of an uncommon C-shaped canal. *J Endod* 2000;26(7):422-4.
 49. Jafarzadeh H, Wu YN. The C-shaped root canal configuration: a review. *J Endod* 2007;33(5):517-23.
 50. Chai WL, Thong YL. Cross-sectional morphology and minimum canal wall widths in C-shaped roots of mandibular molars. *J Endod* 2004;30(7):509-12.
 51. Cheung LH, Cheung GS. Evaluation of a rotary instrumentation method for C-shaped canals with micro-computed tomography. *J Endod* 2008;34(10):1233-8.
 52. Yin X, Cheung GS, Zhang C, Masuda YM, Kimura Y, Matsumoto K. Micro-computed tomographic comparison of nickel-titanium rotary versus traditional instruments in C-shaped root canal system. *J Endod* 2010;36(4):708-12.
 53. Solomonov M, Paqué F, Fan B, Eilat Y, Berman LH. The challenge of C-shaped canal systems: a comparative study of the self-adjusting file and ProTaper. *J Endod* 2012;38(2):209-14.
 54. Ruddle CJ. Three-dimensional obturation of the root canal system. *Dent Today* 1992;11(3):28-30.
 55. Gutmann JL, Rakusin H. Perspectives on root canal obturation with thermoplasticized injectable gutta-percha. *Int Endod J* 1987;20(6):261-70.
 56. Ordinola-Zapata R, Bramante CM, De Moraes IG, Bernardineli N, Garcia RB, Gutmann JL. Analysis of the gutta-percha filled area in C-shaped mandibular molars obturated with a modified MicroSeal technique. *Int Endod J* 2009;42(3):186-97.
 57. Martin H, Fischer E. Photoelastic stress comparison of warm (Endotec) versus cold

58. lateral condensation techniques. *Oral Surg Oral Med Oral Pathol* 1990;70(3):325-7.
59. Caputo AA, Standlee JP. Pins and posts—why, when and how. *Dent Clin North Am* 1976;20(2):299-311.
60. Newton CW, McDonald S. A C-shaped canal configuration in a maxillary first molar. *J Endod* 1984;10(8):397-9.