

## ENDODONTIC MANAGEMENT OF TRAUMATIZED PERMANENT ANTERIOR TEETH WITH RADIOGRAPHICALLY CALCIFIED ROOT CANAL - REPORT OF TWO CASES

Swadhin Raghuvanshi, \* Pradeep Jain, \*\* Husain Kapadia \*\*\*

\* Post Graduate Student, Department of Conservative Dentistry & Endodontics, Sri Aurobindo College of Dentistry, Indore, Madhya Pradesh, India

\*\* Professor & Head, Department of Conservative Dentistry & Endodontics, Sri Aurobindo College of Dentistry, Indore, Madhya Pradesh, India

\*\*\* Post Graduate Student, Department of Conservative Dentistry & Endodontics, Sri Aurobindo College of Dentistry, Indore, Madhya Pradesh, India

### ABSTRACT

The future of teeth with calcified canals appears much brighter today than ever before due to the advancements in diagnostic aids and instrumentation techniques. Dental pulp is prone to dystrophic mineralization; this mineralization can be so extensive that the entire root canal system is obliterated; As a result, root canal treatment can become a difficult if not an impossible task. In an effort to treat a tooth in that condition, the endodontist faces a great challenge that might end up in an accident such as root perforation. Careful approach through dense calcified deposits in the pulp chamber and into the canal may uncover a treatable apical canal remnant. These clinical case reports aims for management of radiographically calcified canals.

**KEYWORDS:** Dental trauma; discolouration; calcified canal; calcific metamorphosis; pulp canal obliteration

### INTRODUCTION

The primary objective of an endodontic therapy is to reduce or eliminate micro-organisms and their by-products from the root canal system. This can be achieved to a great extent by thorough chemo-mechanical debridement, disinfection and obturation of the root canal system. However, this procedure may be difficult to achieve if the pulpal space is obliterated, narrow or calcified. Dental pulp sometimes shows the phenomenon of dystrophic mineralization or calcific metamorphosis.<sup>[1]</sup> Uncontrolled mineralization due to failure of enzyme, pyrophosphatase, reduced capillary permeability and reduced blood

supply leads to calcifications. Root canals in teeth in which calcific deposits have blocked access to the canal (s), treatment efforts are often thwarted. An effort to locate the residual canal may remove large amounts of dentin and there is a risk of perforating or fracturing the root.<sup>[2]</sup>

### CASE REPORT 1

A 26 year old male patient reported to the Department of Conservative Dentistry and Endodontics at Sri Aurobindo College of dentistry with the chief complaint of intermittent pain in upper front region of jaw since 1 month. Patient gave history of trauma 5years back in upper front region of jaw. Clinical examination revealed discoloration and intro-oral sinus with 21# (Fig. 1). Tooth was non tender to vertical and horizontal percussion. Thermal and electric pulp response was negative with 21 whereas adjacent teeth showed normal response to both the tests. Radiographic examination showed Pulp canal obliteration with 21# (Fig. 2). Thus endodontic treatment was planned with 21 and patient consent was taken. A standard access cavity preparation was initiated with a high speed round bur via palatal approach and bur directed towards the localization of the pulp chamber. An access cavity of appropriate shape and size was made using round and tapered diamond bur. #6 K file was introduced into the canal with which canal obliteration was felt in the middle third. C+ files were planned for the initial instrumentation of calcified root canals. Copious amount of 17% EDTA was introduced and #6 C+ file was teased into the canal to establish a "sense of patency". EDTA was expected to soften the deeper hard tissue so that the calcified tissue could be penetrated. While instrumentation, frequent

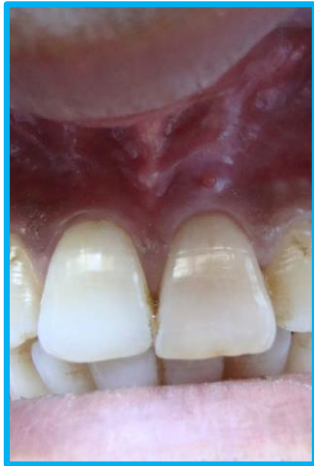

Fig. 1: Discoloration and Intra-oral sinus with 21#

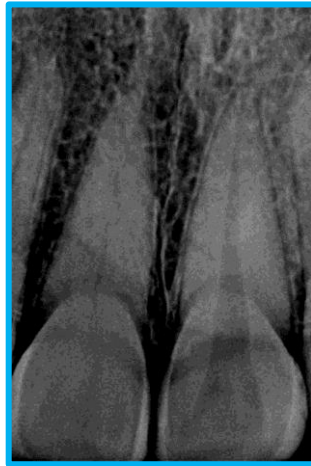

Fig. 2: Pulp canal obliteration with 21#

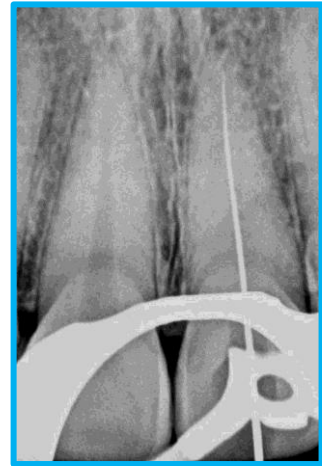


Fig. 3: Working length determination with #10 K file

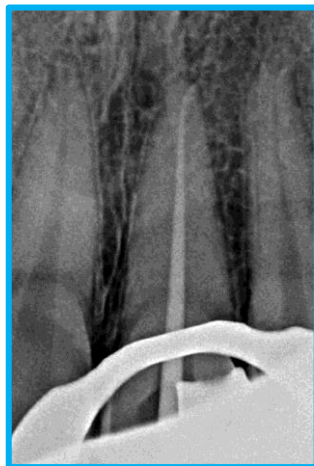

Fig. 4: Master Gutta Percha cone (F2 Protaper; Dentsply)

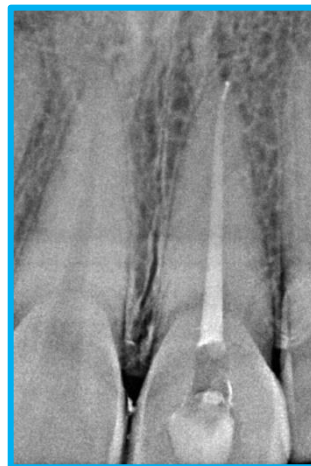

Fig. 5: Obturation followed by GIC restoration

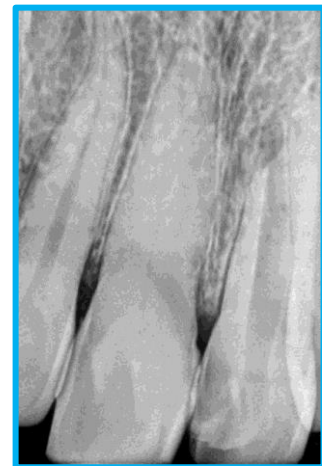

Fig. 6: Pre-op IOPA showing Pulp canal obliteration with 11#

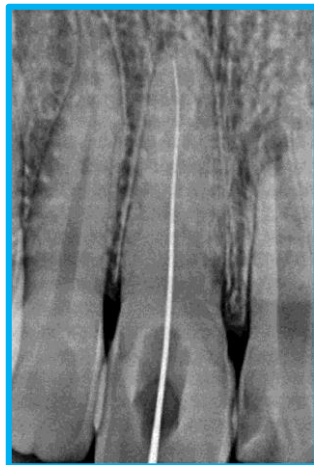

Fig. 7: Working length determination with No 10 K file

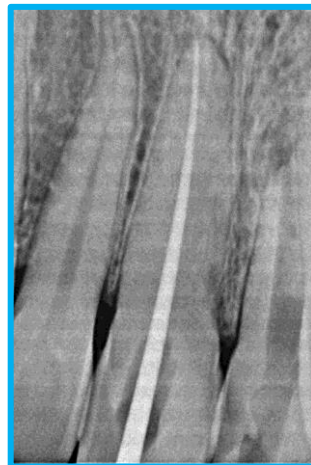

Fig. 8: Master Gutta Percha cone (F2 Protaper; Dentsply)

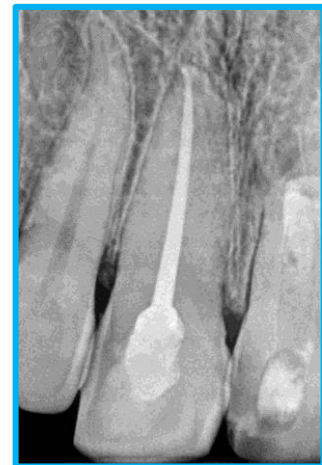

Fig. 9: Obturation followed by GIC restoration

inspection of the file was done to identify any sign of fatigue, irregularity of the flutes or any other defects. #8 C+ file was then used in filling motion along with copious irrigation. When the

instrument became loose then the #8 C+ file was advanced in stem winding motion with irrigants penetrating more apically as the coronal part enlarges. This method of alternate irrigation and

advancement was followed in small increments until the file became free in the canal. With few more attempts the file was able to reach more apically upto the estimated working length. Working length was than determined radiographically (Fig. 3). Once the working length was determined, the canal was prepared using hand K files and rotary Protaper files upto #25 (F2) tip size and 6% taper (Fig. 4). Normal saline altered with 5.25% sodium hypochlorite was syringed into the canal for debridement. 17% liquid EDTA was used to remove smear layer and was again irrigated with normal saline. Final irrigation was done with chlorhexidine. Obturation was completed and access cavity was sealed using Glass ionomer cement (Fig. 5).

### CASE REPORT 2

21 year male patient was reported to the department of Conservative Dentistry and Endodontics at Sri Aurobindo College of dentistry with the chief complaint of discoloration in upper front region of jaw since 6 months. Patient gave history of trauma 2 years back when he met with an accident. Clinical examination revealed discoloration with 11 and was non tender to vertical percussion. Thermal and electrical pulp testing revealed negative pulp response with 11. Radiographic examination revealed pulp canal obliteration with 11 (Fig. 6). Thus endodontic therapy was planned with 11. Access opening was done with the help of long neck taper fissure bur through palatal approach. Since the calcification starts from the labial portion of the crown the access opening was shifted towards the palatal aspect to locate the canal. Once a catch into the canal was obtained, instrumentation with #6 & #8 C+ file was followed as described in the previous case report. #10 K file was slowly advanced to gain the apical patency. Working length radiograph was taken (Fig. 7). Gradual widening of the canal space was done by using #15, #20 & #25 k file. EDTA gel (RC Help, Prime dental products Pvt.Ltd.) was used as a chelating agent each time file was inserted inside the canal. Protaper was used for preparation of coronal and middle third and biomechanical preparation was completed till F2. Master cone radiograph was taken (Fig. 8) and tooth was obturated with F2 Protaper Gutta percha point and AH plus sealer. Post-endodontic restoration was done with Glass

ionomer cement (Fig. 9) and patient was recalled for intra coronal bleaching with 11.

### DISCUSSION

Calcification of the root canal (commonly referred to as pulp canal obliteration, or PCO) is a common sequel following luxation injuries to permanent teeth. Abbott and Yu have discussed the terminology regarding this condition and they have recommended the use of the term "calcification" (rather than "obliteration") as it more accurately describes what is happening, or what has happened, within the root canal. Obliteration implies complete blocking or elimination of the canal which is unlikely, even in a tooth that radiographically appears to have no root canal present.<sup>[3]</sup> In most traumatized teeth that have pulps undergoing calcification, the hard tissue is deposited longitudinally along the dentinal walls of the pulp canal, which gradually diminishes in size until it can barely be observed radiographically. In view of the manner of calcification, there is always a canal present and endodontic management is usually able to be performed, if it becomes necessary, by an experienced clinician.<sup>[3]</sup> In the coronal pulp, calcification usually takes form of discrete-concentric appearance, while in radicular pulp, calcification tends to be diffuse. Pulp canal obliteration occurs commonly following traumatic injuries to teeth. Approximately 4-24% of traumatized teeth develop varying degrees of pulpal calcification that is characterized by the apparent loss of the pulp space radiographically and a yellow discoloration of the clinical crown.<sup>[4]</sup> Procedural errors can arise from overzealous inappropriate attempts to locate the canals. Root wall or furcation perforations can occur even with most careful search. In severe cases regarding perforation, the communication with periodontal tissues must be repaired immediately. Retrograde surgical procedures become conservative compared with perforation or root fracture. To avoid any type of complication in a calcified chamber or canal, all precaution should be taken as well as application of knowledge of the tooth morphology. Though in this case, almost every procedure was done with conventional method, modifications can be done to find and prepare the calcified canals with a variety of explorers, radiograph taken at different levels of bur penetration, magnification, operating microscope,

ultrasonic instruments, various types of C+ files or path file and power assisted rotary instruments. In calcified canals, instrumentation is attempted very carefully because there often remains very fine pathway within the calcified materials. Once a fine file (no. 06, 08 or 10) has reached the correct level, enlargement of the canal is a simple matter. If instrumentation is not possible, one should use an engine driven instrument to grind away the stone with small round, long shanked burs. The DG-16 Endodontic explorer should be used to scout the floor of the pulp chamber. It is relatively 'safe' instrument as it will not gauge solid dentin, but will penetrate the orifice of a calcified canal and resist dislodgement or 'stick' when pulled out. In fact, the endodontic explorer can even be used to 'pick away' at calcification in a more controlled manner than, say, a slow speed round bur. During preparation, gentle pressure should be applied with instruments. Forcing a no.8 file too vigorously may lead to ledge formation or blockage. Frequent inspection of apical curvature of the files is performed to identify any defect. Any file that shows evidence of fatigue or irregularity of the spiral flutes should be replaced.<sup>[5]</sup> The negotiation of small calcified canals is challenging (Dodds et al. 1985). Cvek *et al.*, not surprisingly found that the highest number of irretrievable instrument fractures occurred in totally obliterated root canals. Typically, small files are required for initial path finding; however, these files lack the rigidity required to transverse restricted spaces and can often buckle or fracture when used with vertical watch-winding forces. One approach is to alternate between size 8 and 10 K-files with a gentle watch-winding motion with minimal vertical pressure with regular replacement of the instruments before fatigue occurs. However, a variety of 'pathfinding' instruments are available with this objective in mind. These instruments have various designs, but the most common has a quadrangular cross section that has enhanced rigidity; however, the value of these instruments remains to be demonstrated. In these cases C+ files were used because they have stronger buckling resistance compared to K files, which provides easier negotiation of the calcified canals and easier access to the apical third. The instrument shaft of the C+ files provides as much as a 300% increase in resistance to a buckling force during

penetration. The pyramid shaped tip makes insertion easier during instrumentation and the square section allows better resistance to distortion. Use of chelating agents have been advocated frequently for root canal preparation, especially in narrow and calcified root canals.. Many authors recommend liquid EDTA solution be introduced into the pulp chamber (pipette, cotton pellet) to identify the entrance to calcified canals. EDTA may remain active within the canal for atleast 5 days if not activated. They acts on calcified structure of the tooth only, but care should be taken not to place them in periapical area. Use EDTA {RC Help} as a lubricant when negotiating down calcified canals. A 'crown down' approach has been recommended to improve tactile sensation and better apical penetration. As a general rule, the calcification process as seen in pulpal obliteration occurs in a corono-apical direction so once the initial canal has been captured, an instrument tends to progress more easily as it advances towards the canal terminus.<sup>[6]</sup> Teeth with signs and symptoms with calcified pulp require treatment. If it is possible to introduce endodontic instrument into the canal, conventional root canal treatment is done. In cases where root canal treatment is not possible, surgical approach may be necessary. Smith reviewed the literature concerned with calcific metamorphosis and collected the following data:

- Calcified teeth that were not treated endodontically developed radiographic or clinical symptoms in upto 16% of the cases.
- Studies of the success and failure of conventional endodontic therapy reported failure rates of 10% to 19%.

When these failure rates are compared, it appears that a calcified tooth treated endodontically would have no better chance of success than if it were left alone.

#### CONCLUSION

The cases presented are the example of radiographically unidentifiable pulp chamber that is difficult to treat but manageable via nonsurgical root canal therapy. Periodic radiographs taken between each drilling is mandatory practice to evaluate the depth reached. Good knowledge of tooth morphology, use of appropriate instruments and materials coupled with patience and care are

the secret of success. The use of CBCT and magnification enhance the diagnosis and management of the calcified canal to a greater extent.

#### **CONFLICT OF INTEREST & SOURCE OF FUNDING**

The author declares that there is no source of funding and there is no conflict of interest among all authors.

#### **BIBLIOGRAPHY**

1. Saha S, Patel RP, Agrawal P. Conservative management of calcified canal with maxillary left lateral incisor: A case report. *International journal of womens dentist* 2014;1(1):49-51.
2. Mahajan P, Monga P, Bahunguna N, Bajaj N. Principles of management of calcified canals: *IJDS* 2014;1-5.
3. AJ Moule, CA Moule. The endodontic management of traumatized permanent anterior teeth: a review. *Australian Dental Journal Endodontic Supplement* 2007;52:1.
4. Buntaria SN, Shah V, Patel M, Patel P. Management of Complex Root Canal Anatomy of Maxillary Central Incisor with Calcified Canal. *RRJDS* 2014;2(3):17-23.
5. Islam MA, Wakia T and Alam MS. Management of a maxillary right lateral incisor with calcified canal by conventional endodontic treatment. *CRJMMS* 2013;1(2):23-25.
6. McCabe PS, Dummer PMH. Pulp canal obliteration: an endodontic diagnosis and treatment challenge. *Int Endod J* 2011.
7. Thomas B, Chandak M, Patidar A, Deosarkar B, Kothari H. Calcified Canals – A Review: *IOSR-JDMS* 2014;13(5):38-43.