

## IMPLANT SUPPORTED OVERDENTURE: A CASE REPORT

Sweta Bhandari, \* Anuja Gupta, \*\* Shristhi Sharma, \*\*\* Naveen Choudhary †

\* Dental Practitioner, Smile Dental Clinic, Muscat, Oman

\*\* Senior Lecturer, Department of Prosthodontic, Crown and Bridge, Indian Ocean Dental School and Hospital, Mauritius

\*\*\* Post Graduate Student, Department of Conservative Dentistry and Endodontics, Pacific Dental College & Hospital, Udaipur, Rajasthan, India

† Dental Practitioner Sirvi Dental Care, Hyderabad, Andhra Pradesh, India

### ABSTRACT

The present case reports a patient with prosthodontics rehabilitation consisting of mandibular implant supported overdentures. A 64 year old male patient reported for replacement of missing teeth in both the upper and lower jaws. Clinical and radiographic evaluation revealed partly edentulous upper and lower jaws with significant bone loss and deficiency in height and width. A two stage implant placement protocol was planned. Proposed implant positions and placements were considered and a surgical guide was prepared based on the diagnostic work up. Autopolymerizing acrylic resin was used to prepare a custom tray. Closed tray impression technique was used. Polyether impression material was used to make the final impressions. Record bases and occlusal rims were fabricated on the master casts. Vertical and horizontal jaw relations were recorded. Trial arrangement was checked for esthetic appearance, phonetics, vertical occlusal dimension and centric relation. Denture was fabricated with five spaces for the attachments to be received.

**KEYWORDS:** Implant, overdenture, prosthetic rehabilitation

### INTRODUCTION

While most implant-based treatment has historically focused on fixed prosthetic tooth replacement,<sup>[1]</sup> the multitude of benefits to the edentulous population from implant overdentures is overwhelming in terms of improved function, emotional stability, physical health, and esthetics. Although there still remains a lack of consistency in terms of techniques, prosthetic design, and attachment systems, these aspects have been proven less important to successful outcomes than

once thought.<sup>[2]</sup> Implant supported overdentures are the restoration of choice in complex restorative situations where facial support is needed and are relatively simple to construct, can restore both dental and alveolar tissues, are economical and are able to satisfy the esthetic demands of complex restorative situations.<sup>[3]</sup> The present case reports a patient with prosthodontic rehabilitation consisting of mandibular implant supported overdentures.

### CASE REPORT

A 64 year old male patient reported for replacement of missing teeth in both the upper and lower jaws. Clinical and radiographic evaluation revealed partly edentulous upper and lower jaws with significant bone loss and deficiency in height and width (Fig. 1 & Fig. 2). Advantages and disadvantages of different treatment options were discussed and patient was convinced for an implant supported overdenture. The following decisions were made: root canal treatment for all the remaining upper teeth followed by fixed prosthesis. Placement of 5 implants in the interforamin region of the mandible and fabrication of mandibular implant supported overdenture bar and metal superstructure.

### Surgical Implant Placement

A two stage implant placement protocol was planned. Proposed implant positions and placements were considered and a surgical guide was prepared based on the diagnostic work up. In stage one surgery five (Wane Core) implants were placed based on the bone thickness and anatomical considerations. Sizes of implants were 3.9x11.5mm in anterior regions on all three implants and 4.3x10 on right side and 4.3x8 on left side (Fig. 3). Stage two (three months after the initial implant placement) consisted of exposing the implants after the removal of the cover screws followed by the placement of

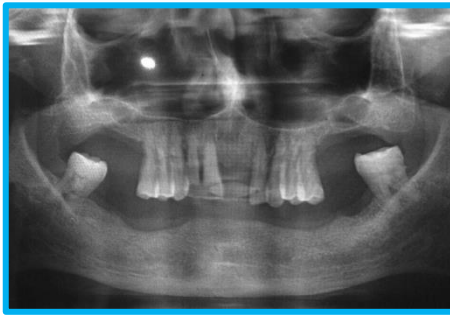


Fig. 1: Pre-operative radiograph of the patient

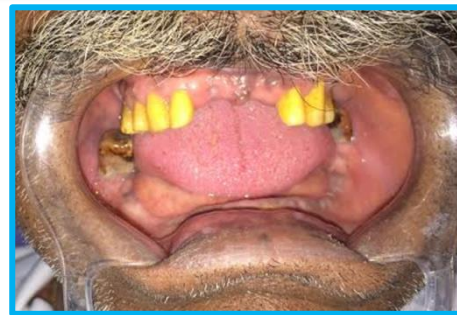

Fig. 2: Pre-operative photograph of the patient

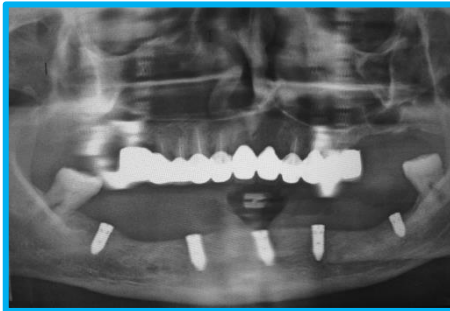


Fig. 3: Post-operative radiograph of the patient

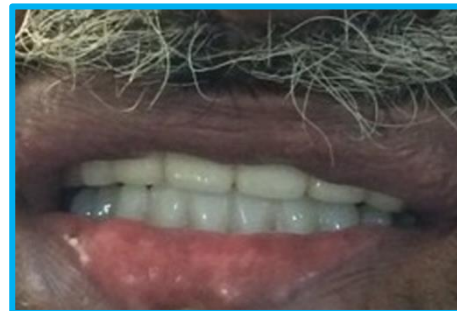

Fig. 4: Post-operative photograph of the patient

prefabricated gingival formers to allow formation of soft tissue cuff. The time period between the surgical phases was used to finish the root canal therapy for all the remaining upper teeth and fabrication of fixed prosthesis.

#### Prosthodontic Procedures

Autopolymerizing acrylic resin was used to prepare a custom tray. Closed tray impression technique was used. Polyether impression material was used to make the final impressions. Record bases and occlusal rims were fabricated on the master casts. Vertical and horizontal jaw relations were recorded. Trial arrangement was checked for esthetic appearance, phonetics, vertical occlusal dimension and centric relation. Denture was fabricated with five spaces for the attachments to be received. A closed mouth procedure was employed to incorporate the ball attachments directly into the denture base. Home care instructions were discussed with the patient during the placement visit and patient was recalled after 1 week for a follow up. At the 1 week follow up the patient expressed his satisfaction with the new denture in terms of its stability and retention. Further recalls at two months and six months showed no complications and the patient reported to be satisfied with the prosthetic rehabilitation.

#### DISCUSSION

The sequela of tooth loss and edentulous arches is residual ridge resorption both in the horizontal

and vertical direction. This ongoing loss of hard and soft tissue is most noticeable in the loss of or facial support: facial esthetics, phonetics, and collapse of vertical dimension. This leads to an aging appearance due to the lack of lip support and decreased facial height. Concurrent with these changes in facial structures are impaired oral function, pain, insufficient retention, and instability of conventional dentures, as well as nutritional and psychological changes.<sup>[2]</sup> The standard treatment for the edentulous patient has been the provision of conventional complete denture. However, complete denture wearers frequently report problems with oral function, typically caused by retention and stability problems of the mandibular prosthesis. An alternative to the conventional denture would be implant supported fixed bridges, hybrid prosthetic dentures and removable overdenture prosthesis. Oral function significantly improves after mandibular implant overdenture treatment.<sup>[4]</sup> Masticatory function is perceived as being considerably impaired by patients with a severely resorbed mandible and conventional dentures. As assessed with the Chewing Ability Questionnaire and the structured interview following a chewing test, masticatory function in patients appears to improve following treatment with an implant-supported mandibular overdenture. Not only the ability to chew all kinds of food significantly improved, but the reduction of pain during

chewing and the reported increased retention of the lower denture was substantial as well.<sup>[5]</sup> The implant supported over dentures helps in preservation of alveolar bone. Crum and Rooney have found that the reduction in the anterior part of the mandible in those patients wearing complete upper and lower dentures amounted to 5.2 mm as compared to 0.6 mm for the overdenture patient.<sup>[6]</sup> The connection between retentive element and the denture can be achieved by indirect and direct method. The indirect technique consists of recording the denture's soft tissue support as well as positioning the implants in relation to the denture, so that the connection of the matrix and the relining procedure can be completed in the laboratory. This method has the potential advantages of the reduced chair time and the use of a single denture base acrylic denture. However the recording and transferring of the implant position with analogs may introduce some errors. Moreover, the patient is without the prosthesis during this time.<sup>[7,8]</sup>

#### CONCLUSION

Implant dentures can be a simple, reliable and cost-effective treatment for edentulous patients. Implant dentures provide the benefits of improved esthetics, phonetics, bone preservation, comfort, all resulting in an improved quality of life for the patient.

#### CONFLICT OF INTEREST & SOURCE OF FUNDING

The author declares that there is no source of funding and there is no conflict of interest among all authors.

#### BIBLIOGRAPHY

1. Branemark PI, Zarb GA, Albrektsson T. Tissue-Integrated Prosthesis: Osseointegration in Clinical Dentistry. Chicago, IL: Quintessence; 1985.
2. Vogel RC. Implant Overdentures: A New Standard of Care for Edentulous Patients Current Concepts and Techniques. *Compend Contin Educ Dent* 2008;29(5):270-6.
3. Naert I, De Clercq M, Theuniers G, Schepers E. Overdentures Supported by Osseointegrated Fixtures for the Edentulous Mandible: A 2.5-Year Report. *Int J Oral Maxillofac Implants* 1998;3:191-6.
4. Joshi S, Pradhan S. Implant-supported mandibular overdenture. *Postgraduate Medical Journal of NAMS* 2009;9(1):54-6.
5. Stellingsma K, Slagter AP, Stegenga B, Raghoobar GM, Meijer HJA. Masticatory function in patients with an extremely resorbed mandible restored with mandibular implant-retained overdentures: comparison of three types of treatment protocols. *Journal of Oral Rehabilitation* 2005;32(6):403-10.
6. Crum RJ, Rooney GE. Alveolar bone loss in over dentures. A 5 year study. *J Prosthet Dent* 1978;6:610-3.
7. Payne AG, Solomons YF. The prosthodontic requirements of mandibular mucosa and implant supported dentures: A review of Literature. *Int J Prosthodont* 2000;13:238-43.
8. Mhatre S, Ram SM, Mahadevan J, Karthik M. Rehabilitation of an edentulous patient with implant supported overdenture. *J Contemp Dent* 2013;3:52-6.