

## DOWNWARD ADVANCEMENT GENIOPLASTY - A CASE REPORT

Ravi Ranjan, \* Sujit Kumar, \*\* Ravindra Kumar, \*\*\* Amit Kumar †

\* MDS, Consultant Oral and Maxillofacial Surgeon, Advanced Oral and Maxillofacial Trauma Centre, Bihar Sharif, Bihar, India

\*\* MD, Consultant Physician, Jeevan Jyoti Super Speciality Hospital, Bihar Sharif, Bihar, India

\*\*\* BDS, Private Practitioner, Advanced Oral and Maxillofacial Trauma Centre, Bihar Sharif, Bihar, India

† Senior Lecturer, Department of Public Health Dentistry, Sarjug Dental College and Hospital, Darbhanga, Bihar, India

### ABSTRACT

Bone correction is thought to be dependent on surgical skills, quality of soft tissues, size and amount of deficiency and choice of method of repair. The concept of the 'ideal' face has changed over time and today, it is only in the last 50 years these techniques have been devised to manipulate the contour of the chin in a reliable and reproducible manner. The knowledge of facial proportions and physiology of the tissues in the peri-oral region enables the general dentist to identify dentofacial deformities and specific chin deformities which will allow him or her to inform their patients regarding the diagnosis and treatment possibilities for correction. The new reference standard in treatment planning is the use of two Computer Aided Designing, Computer-aided milling or machining CAD/CAM technology, orientation sensor documentation of the natural head position and 3D VSP (Virtual Surgical Plan)..

**KEYWORDS:** Genioplasty; osteotomy; anterior mandibular deficiency

### INTRODUCTION

It's a well known fact that deficiency of anterior mandibular cause marked facial deformities, which cause aesthetic and functional problem such as Obstructive Sleep Apnoea. The face is balanced when the superior, middle and inferior thirds are approximately equals in size and the structures within each segment are proportional in size and prominence. Anatomically, the chin is the area below the labiomental fold. A variety of methods are used for correction of retrognathic chin including chin augmentation such as by autologous and alloplast materials and also by using distraction or by osteotomy for anterior mandibular advancement. The horizontal sliding osteotomy was first described by Hofer in 1942.

He used an extraoral incision through which a horizontal osteotomy of the anterior half of the inferior border was completed. Following advancement, transosseous sutures were used for stabilization of the mobilized fragment. Converse in 1950, discussed the feasibility of bone grafts introduced through intraoral approaches.<sup>[1]</sup> Trauner and Obwegeser in 1957 used the horizontal osteotomy through an intraoral incision with degloving of the anterior mandible.<sup>[2]</sup> Hinds and Kent in 1969 were the first to realize and discuss the importance of maintaining the soft tissue attachment along the inferior segment and the role of these attachments in achieving maximal soft tissue change.<sup>[3]</sup> Modern technology using 3-Dimensional (3D) Computer Aided Designing, Computer-aided milling or machining CAD/CAM and manufactured using Stereolithographic Techniques virtual planning for orthognathic surgery has critical advantages compared to conventional treatment planning. 1) Clinician has intrinsic access to more and higher-quality information about the patient's 3D anatomy. 2) Infinite surgical plans can be tested on the 'virtual patient' with the appropriate software. 3) Surgical splints can be manufactured with rapid prototyping techniques in order to accurately transfer the virtual plan to the operating room. It is a powerful communication tool between colleagues and can be used to teach trainees and is a very illustrative method to explain the treatment plan to the patient.<sup>[4]</sup>

### CASE REPORT

28 years female patient reported with the chief complain of retrognathic chin following post-ankylosis 16yrs back. In past the patient had undergone operation for the release of ankylosis 3 years back and the normal mouth opening was achieved. Clinically there was shortening of chin and reduction in facial height. Clinical

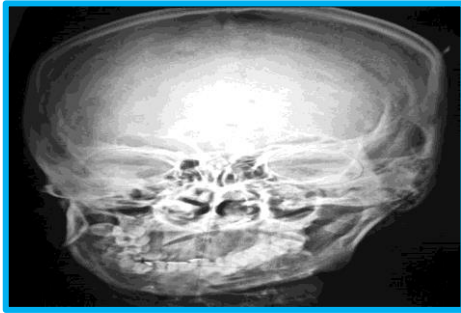

Fig. 1: Pre -op PA x-ray

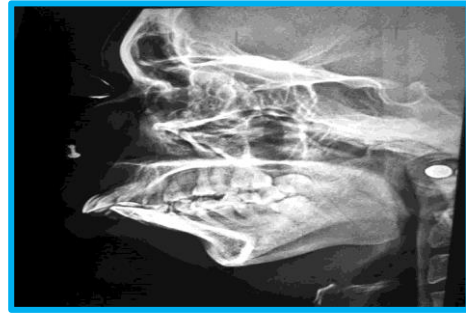


Fig. 2: Pre -op lateral x-ray

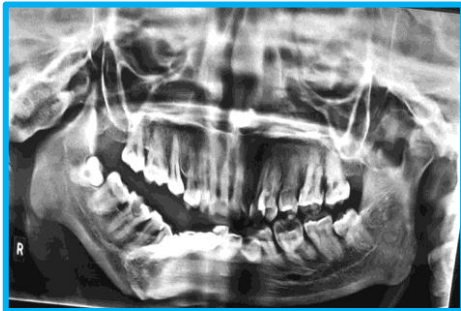

Fig. 3: Pre-op OPG

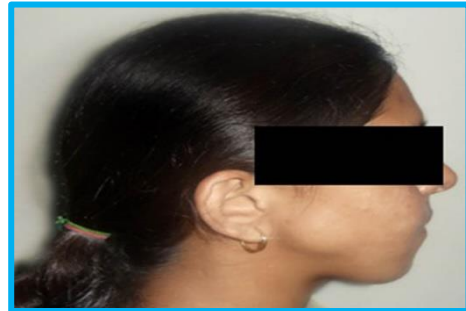

Fig. 4: Pre-op lateral view

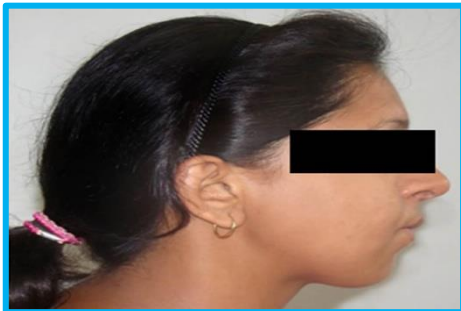

Fig. 5: Post -op lateral view

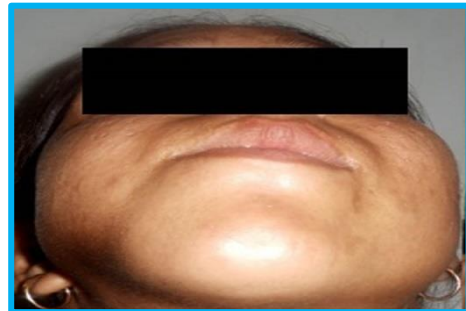

Fig. 6: Pre-op worm's view

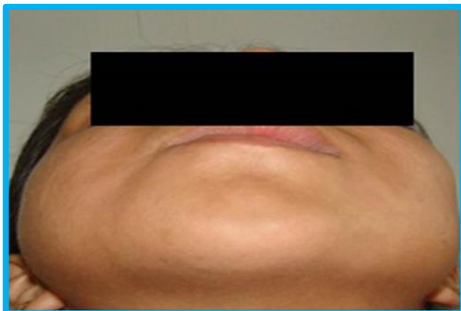

Fig. 7: Post-op worm's view

examination revealed a flat labiomental fold with competent lip. Hence, a sloping facial profile that worsens the lack of chin projection. The mandibular midline was 5 mm to the left of the facial midline and the occlusal plane was not canted. The PA X-ray and Lateral X-ray was taken for defining the site and amount of deficiency tracings on lateral cephalogram were subjected for both hard and soft tissue, the amount needed for advancement 10 mm

according to cephalometrics for orthognathic surgery (COGS) analysis. Grummons analysis was done on P.A cephalogram, the value was 1.5 mm (value for amount required for correction of asymmetry on the right side) (Fig. 1, Fig. 2 & Fig. 3). The patient was taken under General Anesthesia, first the incision was marked intraorally and the site was approached through degloving incision from anterior mandibular premolar to premolar. Exposure of the anterior mandible was done after incising the mucosa and it was undermined, then the mentalis muscle was detached inferiorly towards bone. Sharp incision and reflection of periosteum from the anterior mandible was done after bilateral mental nerves were identified. Midline and paramidline orientation lines were inscribed in the bone before performing the osteotomy with a small bur to facilitate repositioning. According to the planned osteotomy site was marked, initially surgical saw

was used then chisel and mallet to complete the buccal and lingual cortical cuts. After completion of the osteotomy, the inferior fragment was repositioned 3 mm left of the facial midline to correct asymmetry. It was then stabilized using chin plate and was fixed using titanium screws with the advancement of 10mm. Haemostasis was achieved then layer wise closure was done using 3-0 Vicryl was done. Pressure dressing was given. The post-op recovery was uneventful. The patient was reviewed at regular intervals, initially once every week, followed by every two weeks and subsequently once in every month post-operatively. Post-op photograph showed esthetic correction and advancement of chin (Fig. 4, Fig. 5, Fig. 6, Fig. 7).

#### DISCUSSION

The procedure genioplasty primarily has been used to achieve a sliding advancement of the inferior mandibular border for the correction of microgenia in combination with surgery for retrognathic conditions.<sup>[5]</sup> Occasionally, the chin is so deficient that a double *Sliding Horizontal Osteotomy* can be used. The surgical technique involves creation of a stepped intermediate wafer of bone between the inferior fragment and mandible, which is also advanced to provide bony contact between the upper and lower fragments. *Vertical Augmentation* is indicated when it is desirable to increase the lower facial height, especially when the deficit is in the mandibular alveolus or symphysis. It is accomplished by interpositional grafting or alloplastic implant placement between the osteotomized segments following horizontal osteotomy of the mandible. *Alloplastic Augmentation*, the use of alloplasts affords the possibility of not only AP augmentation but also vertical and more importantly lateral augmentation. All kinds and varieties of alloplasts have been used to augment the chin: - silicone, Poly-Tetrafluoroethylene (PTFE), polyamide mesh and High Density Porous Polyethylene (HDPE). The sliding genioplasty for chin augmentation has distinct advantages above the use of alloplastic materials. Some unwanted sequelae associated with the use of alloplastic materials are: 1) Poor chin contour esthetics, 2) Resorption of bone and occasionally teeth under the implant, 3) Mobility to palpation, 4) Both early and late infection, 5) Non infectious

inflammatory responses and unpredictable soft tissue response.<sup>[6]</sup>

#### CONCLUSION

Advancement genioplasty is a safe and effective means of creating esthetic and functional changes by producing alterations in the chin morphology with minimal complications. The knowledge of facial proportions enables the general dentist and health care workers to identify craniofacial deformities which will allow him or her to inform their patients regarding the diagnosis and treatment possibilities for correction. This technique described was found to be a simple and effective method for correction of chin deformity an also helpful in functional problem such as Obstructive Sleep Apnoea. The results obtained here were aesthetically excellent.

#### CONFLICT OF INTEREST & SOURCE OF FUNDING

The author declares that there is no source of funding and there is no conflict of interest among all authors.

#### BIBLIOGRAPHY

1. Bell WH, Proffit WR, White RP. Surgical correction of Dentofacial Deformities. Saunders 1980;1210-80.
2. Trauner R, Obwegeser. Surgical correction of mandibular prognathism and retrognathia with consideration of genioplasty. Oral Surgery 1957;10;677.
3. Hernandez-Alfaro F, Guijarro-Martinez R. New protocol for three dimensional surgical planning and CAD/CAM splint generation in orthognathic surgery: an in vitro and in vivo study Int J Oral Maxillofacial Surgery. 2013;42(12):1547-56.
4. Jung-Yeop Park, Su-Gwan Kim, Seo-Yoon Kim, Sung-Mun Baik. Comparison of genioplasty using Medpor and osteotomy. Oral Surgery Oral Med Oral Pathology Oral Radiol Endod 2010;109:26-30.
5. Sullivan SM. Genial procedures in: Oral and Maxillofacial Surgery. 1999;2:7-10.
6. Bell WH, Brammer JA, McBride KL. Reduction genioplasty: Surgical techniques and soft tissue changes. Oral Surgery Oral Med Oral Pathology 1981;51:471.