

INFLAMMATORY DENTIGEROUS CYST- REPORT OF TWO CASES

N. S. Mamatha, * Bhuvana krishnamoorthy, ** Shruthi R, *** Navin H. K †

* Professor, Department of Oral & Maxillofacial Surgery, Rajarajeshwari Dental College and Hospital, Bangalore, Karnataka, India

** Reader, Department of Oral Medicine and Radiology, ITS-CDSR, Ghaziabad, New Delhi, India

*** Reader, Department of Oral and Maxillofacial Surgery, Rajarajeshwari Dental College and Hospital, Bangalore, Karnataka, India

† Reader, Department of Paedodontia, Rajarajeshwari Dental College and Hospital, Bangalore, Karnataka, India

ABSTRACT

Dentigerous cysts (DC) are of 2 types developmental and inflammatory. Inflammatory dentigerous cyst is found only in the mixed dentition stage. It arises due to the spread of periapical inflammation from the root of a nonvital deciduous tooth to the follicles of the unerupted permanent successors. This report describes two cases of inflammatory DC involving mandibular second premolars due to nonvital deciduous second molar. Management included enucleation in one case and marsupialisation in other. Successful regeneration of bone was found in both cases.

KEYWORDS: Inflammatory dentigerous cyst; Non vital deciduous tooth; Enucleation; Marsupialisation

INTRODUCTION

Dentigerous cyst or follicular cyst is a developmental odontogenic cyst of the jaws and accounts for 20-24%. It is the 2nd most common odontogenic cyst after radicular cyst.^[1,2] A dentigerous cyst encloses the crown of an unerupted tooth by expansion of its follicle and is attached to the neck of the tooth.^[3] It is always associated with an unerupted, impacted, embedded tooth or a developing tooth bud.^[4] There are three primary variants of the DC based on the location of the cyst with respect to the erupting tooth - eruption cyst, circumferential and lateral dentigerous cyst. The inflammatory DC is an additional variant of DC. It arises from the spread of periapical inflammation from an overlying nonvital primary tooth to the unerupted permanent tooth.^[5,6] Mandibular premolar is the tooth most commonly involved. The inflammatory DC was reported first by Shaw and colleague (1980), who suggested the term "inflammatory follicular cyst". They found that

the most common sequel to untreated periapical inflammations in a primary tooth was intrafollicular penetration of inflammatory elements to the underlying permanent tooth. Subsequently proliferation of the reduced enamel epithelium is stimulated by the inflammatory process.^[7]

CASE REPORT 1

A 9 year old boy presented to a private dental clinic with the chief complaint of a slow growing swelling in the lower left region of the face since 2 months. The child had no significant family or medical history. On extra oral examination no obvious swelling was observed. Intra oral examination revealed mixed dentition stage, mandibular left deciduous 1st and 2nd molar were carious, the latter being grossly destroyed. The buccal vestibule on the left side of the mandible was obliterated due to a swelling that extended from medial aspect of 73 involving 74 and 75 till the medial aspect of 36, measuring approximately 2x2 cms in diameter. The mucosa over the swelling was normal. On palpation the swelling was non tender. On percussion deciduous molars were non tender. Solitary left submandibular lymph node was enlarged, non tender and firm on palpation. Panoramic radiograph revealed carious 74 and grossly destructed 75. There was a well defined radiolucency in the periapical region of 75 and also surrounding the tooth bud of the developing 35 that was displaced distally. There was resorption of the root of 75 (Fig. 1). On aspiration straw coloured fluid was obtained. Provisional diagnosis of dentigerous cyst was made. Under general anaesthesia, through intra oral approach, both the mandibular deciduous left molars were extracted. The distally displaced 35 was unlikely to erupt into the oral cavity and hence it was removed along with cyst enucleation. Post operative wound healing was uneventful. At one year follow up first premolar

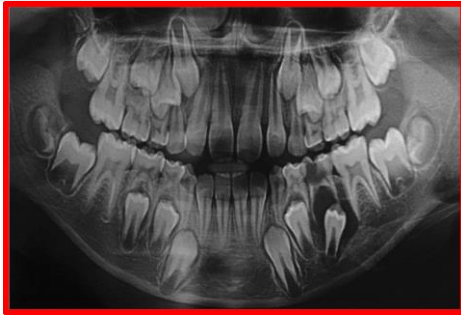


Fig. 1: Panoramic radiograph shows the grossly destroyed 75. A well-defined unilocular radiolucency with sclerotic borders can be seen in the periapical region of 75.

The tooth bud of 45 is completely enclosed within the lesion and is also displaced distally

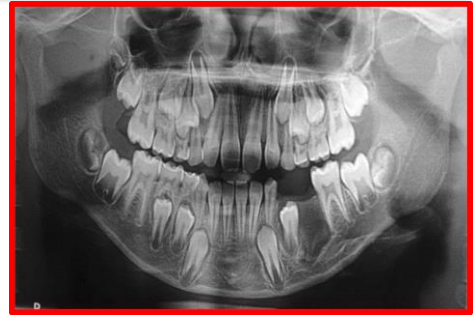

Fig. 2: One year post-operative panoramic radiograph showing the healed surgical defect following enucleation of the lesion and extraction of 74, 75 and 35

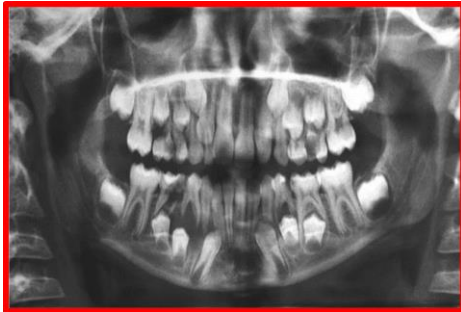

Fig. 3: Panoramic radiograph shows dental caries involving the pulp in 85 and well defined periapical radiolucency in the region of 84 and 85 involving the furcation areas of the teeth.

There is resorption of the roots of 85 and distal displacement of the tooth bud of 44

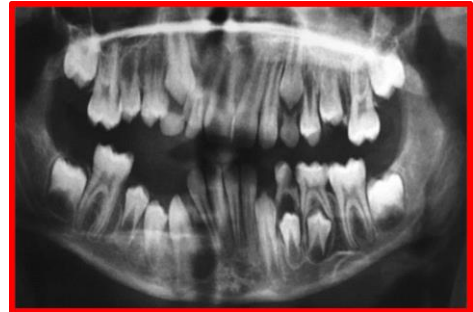


Fig. 4: Panoramic radiograph taken at 1 year follow up showing premolars erupting into position and bone cavity healed completely

is erupting into the oral cavity and bone cavity is completely ossified (Fig. 2).

CASE REPORT 2

An 8 year old boy reported to a private dental clinic, with a chief complaint of swelling in the lower right posterior part of the face. The child had no significant medical history. On examination extra oral swelling was present in the lower third of the face on right side, lateral to angle of mouth. The swelling measured 2x2cms, with diffuse margins. On palpation the swelling was non tender and firm in consistency. On intraoral examination, lower right deciduous molars were carious, 2nd molar grossly destroyed. The buccal vestibule was obliterated, swelling extended from the mesial side of canine to the mesial side of the first molar. It was non tender and firm on palpation. Panoramic radiograph revealed carious lower deciduous molar 2nd molar with periapical radiolucency extending around the 2nd premolar tooth bud (Fig. 3). On aspiration straw coloured was obtained. Provisional

diagnosis of dentigerous cyst was made. Under general anaesthesia though intra oral approach lower right deciduous molars were extracted, cystic contents were drained and marsupialisation of cyst was done. Cavity was packed with bismuth iodine paraffin paste and was changed once in a week. By 4th week cavity was completely epithelised. Healing was uneventful. At 1 year follow up, premolars are erupting and bone cavity is completely ossified (Fig. 4).

HISTOPATHOLOGICAL EXAMINATION

The cystic lining in both cases showed nonkeratinized stratified squamous epithelium, odontogenic epithelial islands in subepithelial connective tissue along with inflammatory cells in the epithelial lining.

DISCUSSION

The three possible mechanisms of histogenesis of dentigerous cyst are described by Benn and Altini. Developmental DC arises from dental follicle and becomes secondarily inflamed by a nonvital tooth. The second type develops from

radicular cyst which forms at the apex of a nonvital deciduous tooth. The permanent successor erupts into a radicular cyst and results in DC that is extra follicular in origin. Third is due to periapical inflammation from nonvital deciduous tooth or other sources which spreads to involve follicle of permanent successors, as a result of inflammatory exudates, dentigerous cyst formation occurs.^[2,5,6] In the case 1, enucleation was the treatment option. After extraction of deciduous molars, 2nd premolar tooth bud was found displaced distally and free floating in the cavity, hence enucleation and removal of 2nd premolar was considered. Removal of permanent tooth is preferred only if it is badly displaced or arrested developmentally.^[8] Enucleation of cyst without removal of permanent tooth and use of lingual space maintainer is another treatment option.^[9] In case 2, there was no much displacement of 2nd premolar tooth bud, so marsupialisation was considered. This procedure allowed eruption of the tooth into the oral cavity. Marsupialisation allows eruption of a impacted, unerupted tooth if sufficient space exists.^[4] In both the cases healing was uneventful. Another treatment option reported for inflammatory DC is extraction of the nonvital carious primary tooth and decomposition of the cystic cavity and the patient is followed up until eruption of the permanent teeth and bony consolidation of the cyst.^[6] The inflammatory DC is more commonly associated with second deciduous molars. This prevalence is probably because of greater caries susceptibility. The close relationship between the deciduous 2nd molar and the follicle of the successors 2nd premolars facilitate spread of infection compared to other primary teeth.^[10] As long as cyst remains small, it is asymptomatic and usually found by chance when radiographs are taken to investigate a missing tooth, delayed tooth eruption or for orthodontic reasons. Hence it is suggested to watch for a dentigerous cyst as it can be associated with an impacted, unerupted and supernumerary and even pulp treated primary teeth. The differential diagnoses are periapical cyst, odontogenic keratocyst and unicystic ameloblastoma. These entities are frequently found in molar area of the lower jaw and in the 2nd and 3rd decade of life.^[6] Inflammatory dentigerous cyst is found commonly in mixed

dentition stage and in mandibular 2nd premolar region.^[6,10]

CONCLUSION

Dentigerous cysts can attain considerable size, there is a possible development of tumour from dentigerous cyst lining, often they are asymptomatic and discovered on routine radiographic examination. Hence early diagnosis and management is of paramount importance in reducing the morbidity. Inflammatory DC should be considered in the differential diagnoses of periapical radiolucencies occurring in the jaws.

BIBLIOGRAPHY

1. Deepak PB, Tarulatha RS. Dentigerous cysts of inflammatory origin-A case report. The Internet Journal of Dental Science, 2009;7(2).
2. Jha AK Management of Dentigerous cyst in an 11 years old child-A case report. Journal of Dentistry Defence Section. 2011;6(1):64-66.
3. Shear M, Speight P. Cysts of the oral and maxillofacial regions 4th edition. Black well publishing, Bristol; 2007.
4. Ertas U, Yavuz MS. Interesting eruption of 4 teeth associated with a large dentigerous cyst in mandible only marsupialisation. J Oral Maxillofac surg. 2003;61:728-730.
5. Benn A, Altini M, Dentigerous cyst of inflammatory origin, a clinicopathologic study. Oral Surg Oral Med Oral Path Oral Radiol/Endod. 1996;81:203.
6. Kozelj V, Sotosek B. Inflammatory dentigerous cysts of children treated by tooth extraction and decompression-report of four cases. Br Dent J. 1999;187(11):587-590.
7. Langlais RP, Langland OE, Nortje CJ. Diagnostic images of the jaws, Periapical radiolucencies without opacities, Williams and Wilkins, Philadelphia 1995, 286-91.
8. Brook AH, Winter GB. Development arrest of permanent tooth germs following pulpal infection of deciduous teeth. Br Dent J. 1975;139:9-11.
9. Arita K, Amo M, Kamada K, Yanagawa T, Nishino M. Dentigerous cysts of children treated by cyst wall enucleation, report of eleven cases. Shoni Shikagaku Zanshi. 1989;27:197-207.

10. Nagaveni NB, Umashankar KV, Radhika NB. Inflammatory Dentigerous cyst associated with an endodontically treated primary second molar. A case report. Archives of orofacial sciences. 2011;6(1):27-31.

Source of Support: Nil
Conflict of Interest: Nil